circumferential esophageal ulcerations were present in the other two case reports (including ours), and could represent an advanced disease state as these patients died of disease complications despite immunosuppression.[4] Endoscopic biopsies were nonspecific and not diagnostic in four out of the six cases (including ours). It has been suggested that endoscopic biopsies are superficial and may not be diagnostic.[3] Interestingly, in four of these reports (including ours), dysphagia was the prominent symptom. Esophageal involvement can also be the presenting symptom of GPA as seen in our case.

Physicians need to be aware of GPA as a cause of esophageal ulcers, to prevent delay in diagnosis and treatment. In the present case, the decision to administer high dose steroids had to be weighed against the risk of precipitating GI hemorrhage. Management of such cases is essentially high dose immunosuppression, as generally used in the induction phase of vasculitis. Esophageal strictures may require serial dilatation.[5] This report highlights esophageal involvement as a rare presentation of GPA.

SUCEENA ALEXANDER[1],
EBBY GEORGE SIMON[2],
DEEPAK BURAD[3],
SANTOSH VARUGHESE[1],
VINOI GEORGE DAVID[1],
SHIBU JACOB[1],
GOLLA SUDHAKAR[1],
VEERASAMY TAMILARASI[1],
CHAKKO KORULA JACOB[1],
CHARLES D PUSEY[4],

*Correspondence: Dr. Suceena Alexander,*
*Department of Nephrology[1], Gastroenterology[2],*
*General Pathology[3],*
*Christian Medical College,*
*Vellore, India and*
*Department of Medicine[4],*
*Imperial College, London*
*Email: suceena@gmail.com*

## References

1. Falk RJ, Gross WL, Guillevin L, Hoffman GS, Jayne DR, Jennette JC, et al. Granulomatosis with Polyangiitis (Wegener's): An alternative name for Wegener's Granulomatosis. *Arthritis Rheum*. 2011;**63**:863–4.
2. Godman GC, Churg J. Wegener's granulomatosis: pathology and review of the literature. *AMA Arch Pathol*. 1954;**58**:533–53.
3. Camilleri M, Pusey CD, Chadwick VS, Rees AJ. Gastrointestinal manifestations of systemic vasculitis. *Q J Med*. 1983;**52**:141–9.
4. Fallows GA, Hamilton SF, Taylor DS, Reddy SB. Esophageal involvement in Wegener's granulomatosis: a case report and review of the literature. *Can J Gastroenterol*. 2000;**14**:449–51.
5. Reddy RS, Biyyani S, Pauskar P, Fahmy NM, King JF. Extensive gastrointestinal tract and thyroid involvement with Wegeners granulomatosis. *Indian J Gastroenterol*. 2007;**26**:290–1.

# Non communicating gastric antral duplication cyst presenting with hematemesis due to large antral ulcer

## Introduction

Gastrointestinal duplications are congenital anomalies due to defective canalization of the GI tract. They may occur at any site from mouth to anus, but with variable frequency.[1] Gastric duplications are among the relatively rare duplications, and are usually difficult to diagnose and treat.We report here a case of gastric duplication, which presented as a large antral gastric ulcer with hematemesis.

Case: A 7-year old boy came to us with a history of periumbilical and epigastric pain abdomen, which started 2 years prior to presentation, and lasted for 6 months, and was being managed with proton pump inhibitors. There was no history of

Figure 1: USG showing duplication cyst (Typical gut signature)

NSAID intake. Investigations including ultrasonography abdomen and contrast enhanced CT abdomen,which was unremarkable.A fresh episode of epigastric pain and recurrent non-bilious vomiting started one month prior to referral and was managed symptomatically. A day prior to admission he had 3 episodes of minor hematemesis, not requiring blood transfusion. On examination, he had normal anthropometry and was hemodynamically stable. Except for epigastric tenderness, systemic examination was normal. His hemoglobin was12.9g/dL, total leukocyte count: 8900/µL, platelet counts: 335000/µL and normal liver function tests. USG abdomen showed a cystic lesion in the gastro-hepatic ligament, in the antro-pyloric region

Figure 2: Endoscopy showing large antral ulcer

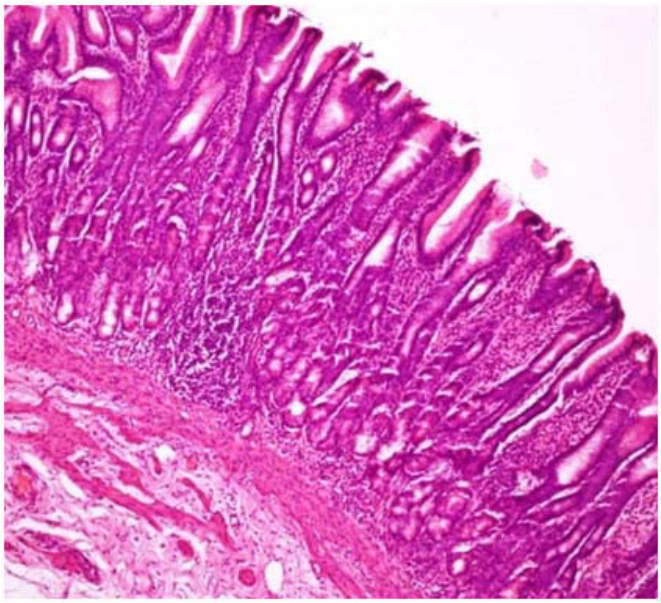

Figure 3: Microphotograph of the cyst showing gastric type of mucosa having antral type of glands mixed with occasional parietal cells (H&E, x20)

along the lesser curvature (**Figure 1**). The CECT abdomen done 1.5 years agoreported normal at the time, when reviewed, showed the same lesion. Upper gastrointestinal endoscopy revealed a large antral ulcer with gastric wall edema (**Figure 2**). Evaluation for H.pylori was negative and serum gastrin assay was 74.6pg/mL (normal range 13-115pg/mL). He continued to be treated withPPIs and repeat endoscopy after 3 weeks just before surgery showed healing of the ulcer. Laparotomy revealed a gastric duplication cyst in the wall of the antrum of the stomach with no apparent internal communication. The patient underwent cyst excision along with adjacent stomach wall followed by end to transverse anastomosis of the pylorus and first part of the duodenum. Histopathological examination of the cyst was consistent with gastric duplication cyst (**Figure 3**). The post-operative period was uneventful and he was discharged on day 7 andnormal feeding advised. He has remained asymptomatic thereafter for 6 months at the time of reporting and repeat endoscopy revealed a normal gastric mucosa.

## Discussion

Gastrointestinal duplications are rare GI anomalies with the frequency of 1 per 4500 live births, the ileum being the most common site followed by the foregut, least commonly seen in the tongue and pharynx[1]. Most children present before the age of one year, with symptoms depending on the site of involvement and associated complications.[1,2] Split notochord theory and incomplete recanalisation of the primitive gut have been postulated as the embryological basis for the development of the duplications.[3] They may be cystic or tubular; communicating or non-communicating. Cystic and non-communicating ones are reported as more frequent than tubular and communicating duplications. The mucosa is usually the same as that of the adjacent normal bowel; however a different type of mucosal lining is not infrequent. Complications include gastrointestinal bleeding, secondary infection; compression of adjacent normal bowel; pain; and rarely malignant transformation has been noted in adults. Hemorrhage and infection tend to occur in communicating duplications. Bleeding results due to ulceration of the surrounding normal mucosa by the gastric acid secreted by the mucosal lining.USG is considered an accurate investigative tool and frequently shows an aperistaltic bowel like structure with a lumen and an echogenic lining. However, contrast tomography/magnetic resonance imaging or even endoscopic ultrasonography (EUS)

may help in the diagnosis if USG is non contributory. The 99m technetium pertechnates scan are also useful to pick up gastric mucosa lined duplication cysts. Excision is the treatment of choice as duplications will continue to be symptomatic unless removed. Isolated GI duplication has an excellent post surgery prognosis[4].Exact cause for large antral gastric ulcer is not known; however a rare physiological alteration similar to retained antral syndrome, a syndrome of uninhibited gastrin secretion and refractory gastric ulcers as seen after surgery for peptic ulcer disease has been contemplated[5].

SRIKANTH KP[1],
THAPA BR[1],
SADHNA B LAL[1],
PREMA MENON[2],
KUSHALJIT SODHI[3],
KIM VAIPHEI[4],
RAO KLN[2]

*Correspondence: Prof Thapa BR*
*Department of Pediatric Gastroenterology[1], Pediatric Surgery[2], Radiology[3], and Histopathology[4],*
*Post Graduate Institute of Medical Education and Research*
*Chandigarh-160012, India*
*Email: brthapa1@yahoo.co.in*

## References

1. Gross RE, Holcomb GW, Farber S. Duplications of the alimentary tract. *Pediatrics* 1952;**9**:448–68.
2. Bower RG, Sieber WK, Kiesewetter WB. Alimentary tract duplication in children. *Ann Surg*. 1978;**188**:669–74.
3. Bentley JFR, Smith JR. Developmental posterior enteric remnants and spinal malformations. *Arch Dis Child*. 1960;**35**:76–86.
4. Stringer MD, Spitz L, Abel R, Kiely E, Drake DP, Agrawal M, et al. Management of alimentary tract duplication in children. *Br J Surg*.1995;**82**,74–8.
5. Gibril F, Lindeman RJ, Abou-Saif A, Shojamanesh H, Roy PK, Peghini PL, et al. Retained gastric antrum syndrome: a forgotten, treatable cause of refractory peptic ulcer disease. *Dig Dis Sci* 2001;**46**:610–7.

# Anaphylactic reaction to omeprazole

## Introduction

Proton pump inhibitors (PPI), the most potent inhibitors of gastric acid secretion, have revolutionized the treatment of acid related disorders, including gastroesophageal reflux disease, peptic ulcer disease, and gastropathy induced by nonsteroidal anti-inflammatory drugs (NSAIDs). They are combined with antibiotics to eradicate Helicobacter pylori. Since the introduction of omeprazole, a proton-pump inhibitor (PPI), in 1988, several other PPIs i.e., lansoprazole, rabeprazole, pantoprazole, and esomeprazole have been developed. They are generally well tolerated, with minimal adverse effects, most of which are related to the drug's pharmacokinetic interaction profiles[1]. Although hypersensitivity reactions are rare, several anaphylactic reactions have been reported[2-5].Some reports describe the presence of cross-reactivity between different members of the group, although no definite pattern has emerged[6-9]. We present a case of omeprazole induced anaphylactic reaction which was managed uneventfully.

## Case report

A 64-year-old woman received a prescription for omeprazole 20 mg capsules from her general practitioner for peptic symptoms. About 55 minutes after taking the first capsule, she developed malaise, periorbital edema, erythema of the skin, pruritus, nausea, and vomiting. On presentation to our hospital her pulse was feeble and blood pressure was not recordable. After treatment with injection adrenaline (1:1000dilution) 0.5mg subcutaneously, injection hydrocortisone intravenously, injection pheniramine intravenously, injection normal saline infusion, she recovered uneventfully. The acute onset of urticaria, edema, and hypotension and a close temporal association of these clinical signs with the ingestion of the tablet in our patient allow this reaction to be classified as anaphylactic shock, according to the Council for International Organizations of Medical Sciences.[10]

## Discussion

Anaphylactic shock is classified as a sudden and substantial decrease of arterial blood pressure in close temporal association with exposure to a drug or other substance, which is not a vasovagal reaction and is not induced by a direct effect of a drug on cardiovascular function or hemodynamic regulation. Alternatively, the term anaphylactic shock may be used if