where the plexuses are unable to contain the high venous pressure, there can be torrential vaginal bleeding.[7] Portal biliopathy and cholangiopathy with protein-losing enteropathy are also associated with extra-hepatic portal hypertension.[8] This is triggered by the mechanical compression of the bile ducts by portal cavernoma and secondly by ischemic injury to the bile duct wall leading to pericholedochal inflammation and fibrosis.[8,9] Our patient experienced increased bleeding per vagina which we thought to be either dysfunctional uterine bleeding or portal hypertension, since no other cause was found. The patient improved with treatment for dysfunctional uterine bleeding and she did not have any other symptoms directly related to portal hypertension. She was kept on close follow-up. Adult patients with chronic extra-hepatic portal vein obstruction can remain asymptomatic up till four to twelve years after the obstruction and commonly present with variceal bleeds.[10] Although there is imaging evidence of portal biliopathy in more than 80% patients with extra-hepatic portal vein obstruction, only a minority (5%) develop symptoms.[11] Our patient did not have any symptoms related to portal biliopathy. In conclusion, accessory hepatic lobe is a rare cause of portal vein obstruction. Contrast enhanced CT, MRI and MRCP can help establish the diagnosis.

ANURADHA CHANDRAMOHAN
ESTHER L PACHUAU
ANU EAPEN

Correspondence: Dr. Anuradha Chandramohan
Department of Radiology, Christian Medical College,
Vellore, Tamil Nadu – 632004, India
Email: anuradhachandramohan@gmail.com

References

1. Matley PJ, Rode H, Cywes S. Portal vein obstruction by ectopic liver tissue. *J Pediatr Surg*. 1989;**24**:1163–4.
2. Jambhekar K, Pandey T, Kaushik C, Shah HR. Intermittent torsion of accessory hepatic lobe: An unusual cause of recurrent right upper quadrant pain. *Indian J Radiol Imaging*. 2010;**20**:135–7.
3. Massaro M, Valencia MP, Guzman M, Mejia J. Accessory hepatic lobe mimicking an intra-abdominal tumor. *J Comput Assist Tomogr*. 2007;**31**:572–3.
4. Rendina EA, Venuta F, Pescarmona EO, Martelli M, Ricci C. Intrathoracic lobe of the liver. Case report and review of the literature. *Eur J Cardiothorac Surg*. 1989;**3**:75–8.
5. Elmasalme F, Aljudaibi A, Matbouly S, Hejazi N, Zuberi MS. Torsion of an accessory lobe of the liver in an infant. *J Pediatr Surg*. 1995;**30**:1348–50.
6. Goor DA, Ebert PA. Anomalies of the biliary tree. Report of a repair of an accessory bile duct and review of the literature. *Arch Surg*. 1972;**104**:302–9.
7. McHugh PP, Jeon H, Gedaly R, Johnston TD, Depriest PD, Ranjan D. Vaginal varices with massive hemorrhage in a patient with nonalcoholic steatohepatitis and portal hypertension: Successful treatment with liver transplantation. *Liver Transpl*. 2008;**14**:1538–40.
8. Gauthier F. Recent concepts regarding extra-hepatic portal hypertension. *Semin Pediatr Surg*. 2005;**14**:216–25.
9. Besa C, Cruz JP, Huete A, Cruz F. Portal biliopathy: a multitechnique imaging approach. *Abdom Imaging*. 2012;**37**:83–90.
10. Sarin SK, Agarwal SR. Extrahepatic portal vein obstruction. *Semin Liver Dis*. 2002;**22**:43–58.
11. Sarin SK, Sollano JD, Chawla YK, Amarapurkar D, Hamid S, Hashizume M, et al. Consensus on extra-hepatic portal vein obstruction. *Liver Int*. 2006;**26**:512–9.

Bleeding lingual varix in a patient with cirrhosis

Introduction

The association of lingual varix with portal hypertension and liver cirrhosis is rare. We report a patient with alcoholic liver cirrhosis who developed lingual varix followed by intermittent bleeding.

Case report

A 47-year-old male with alcoholic liver cirrhosis and portal hypertension of four years duration was admitted with history of spitting of fresh blood since one week. The patient gave history of a similar episode two months back which had stopped spontaneously, and of a bluish soft swelling on the infero-lateral surface of the tongue since four months ago. Examination of oral cavity revealed presence of prominent, tortuous, bluish blood vessels (**Figure 1**). The patient complained of no discomfort or change in size of the lesion. His medical history did not reveal any blood dyscrasias. System examination and investigations including ultrasound revealed presence of liver

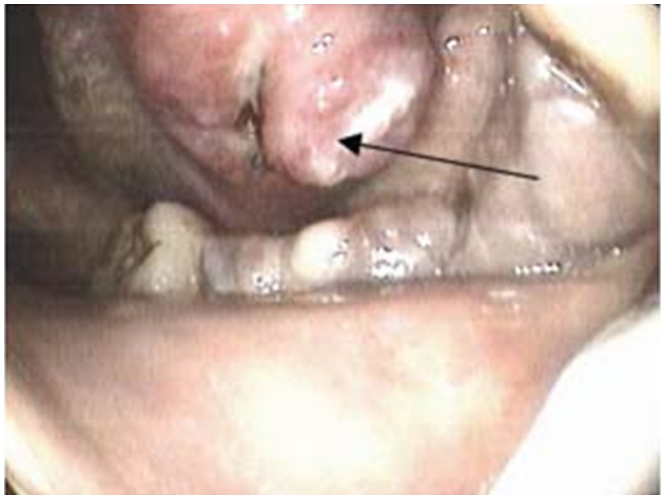

Figure 1: Lingual varix on the lateral aspect of tongue

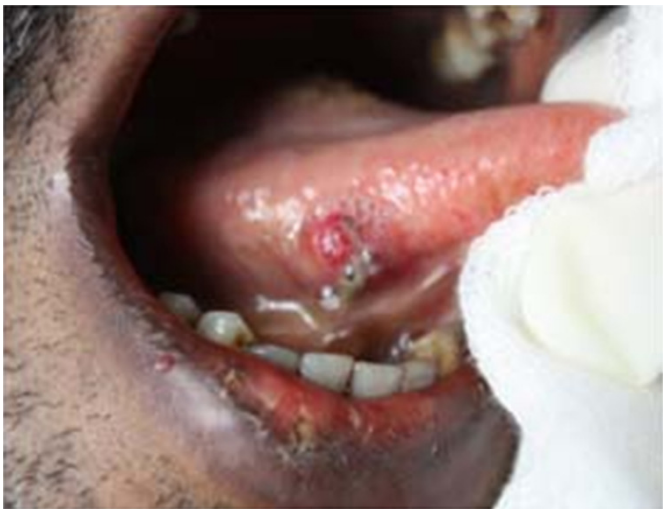

Figure 2: Lingual varix after control of bleeding by suturing

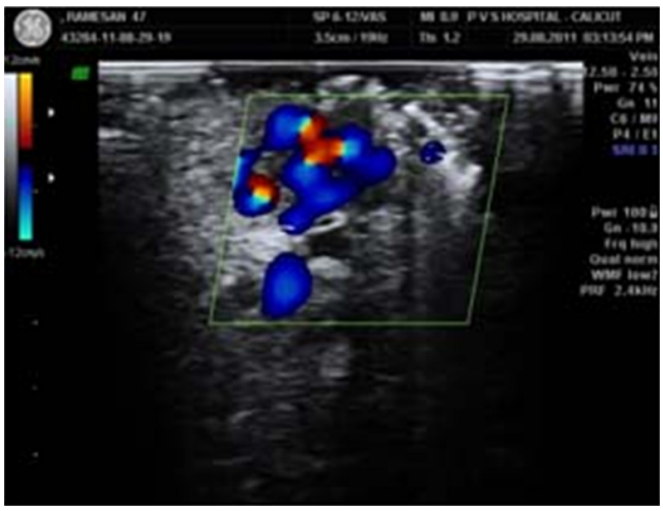

Figure 3: Doppler study showing lingual varix

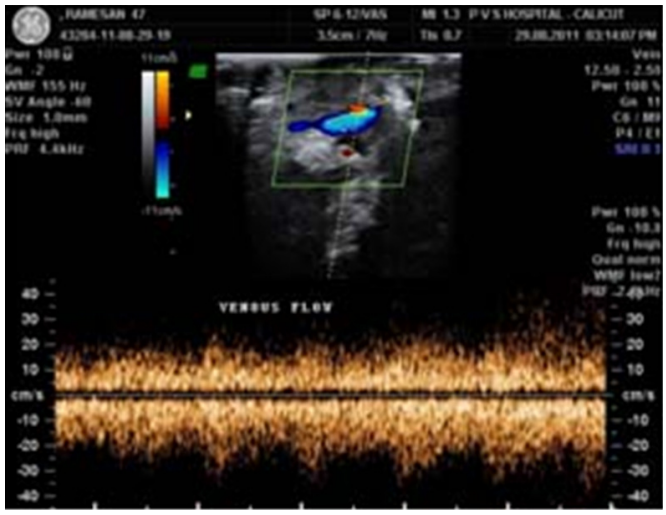

Figure 4: Doppler study of lingual varix with typical flow pattern

cirrhosis and oesophago-gastro-duodenoscopy showed grade 2 esophageal varices. Chest X-ray did not reveal any SVC obstruction. Doppler study of lingual swelling showed it to be variceal in origin with dilated venous channels (**Figures 2 and 3**). Bleeding was controlled by suturing the varix (**Figure 4**).

Discussion

A varicosity is an enlarged and tortuous vein, artery or lymph vessel with a purple to red appearance. Varicosities are related to age, tissue compromise and increased venous pressure. Oral varicosities are usually seen on the lateral border of the tongue and floor of the mouth, mostly in persons 40 years or above in age. They may occasionally be seen in cheeks and lips as well.[1] Ettinger and Mandersen found that the incidence of varicosities increases with age.[2] It was Koscard and coworkers who concluded that the diminished capillary elastic support which allowed them to dilate and lead to varicosity formation. Another report has showed sublingual varices to be associated with portal hypertension secondary to hepatic cirrhosis.[3] Varices formation can be explained by three reasons: firstly varices can arise spontaneously, unrelated to any systemic disease; secondly, they may be a manifestation of cardiopulmonary disease[4] and lastly, there may be an unrecognized anastomotic connection between the lingual venous drainage and portal circulation.

GEORGE JEFFEY
S ABHISHEK
G AYYAPPAN
K SANDESH
TM RAMACHANDRAN

Correspondence: Dr. TM Ramachandran
Department of Gastroenterology, Government Medical College, Calicut, Kerala, India

Email: jeffeygeorge@gmail.com

References

1. Herbert Z, Klienmen, Danville. Lingual varicosities. *Oral Surg*. 1974;**23**:546–8.
2. Ettinger RL, Manderson RD. A clinical study of sublingual varices. *Oral Surg Oral Med Oral Pathol*. 1974;**38**:540–5.
3. Jassar P, Jaramillo M, Nunez DA. Base of tongue varices associated with portal hypertension. *Postgrad Med J*. 2000;**76**:576–7.
4. Burket LW. Oral medicine. 4th ed. Philadelphia: JB Lippincott;1961.p.146.

Diagnosis of an early stage IPSID using Syndecan 1

Introduction

IPSID, traditionally termed Mediterranean lymphoma or Alpha Heavy Chain Disease, is a B cell neoplasm that arises in small intestinal mucosa-associated lymphoid tissue (MALT). It is characterized by the production of an unusual IgA heavy chain protein, called á heavy chain, which is secreted by plasma cells and is detectable in various body fluids. Patients may present in the second and third decades of life with chronic diarrhea, malabsorption, weight loss and abdominal pain. Clubbing of the fingers and nutritional deficiencies are characteristic, and palpable abdominal masses may be present.[1,2] The most frequently affected sites are the duodenum and upper jejunum, but the pathology is diffuse with a mucosal cellular infiltrate involving large segments of the intestine and sometimes the entire length.[1]

Case report

A 47-year-old male presented with a one week history of upper abdominal pain, vomiting and fever. He had lost 6 kilograms of weight over the previous one month. He did not have any co-morbid illnesses. Neither did he smoke nor did he consume alcohol. Physical examination revealed that he was febrile, had tachycardia and clubbing. Abdominal examination revealed epigastric tenderness. Haemoglobin was 10.5 gm% and serum albumin was 3 gm%. An erect abdominal X-ray was normal. Contrast enhanced CT scan of the abdomen was also normal. In view of the persistent symptoms an upper GI enteroscopy was performed, which revealed multiple ulcers in the proximal jejunum with mucosal edema. Biopsies from the ulcers showed a cellular mucosal infiltrate with destruction of the crypts and a reduction in crypt density, villi were short and broad (**Figure 1**). Immunohistochemistry showed cells which were LCA (Leukocyte common antigen) positive, CD3 (T cell marker) negative, CD20 (B cell marker) focally positive, IHC for kappa and lambda light chains was negative, Ki 67 showed low expression, and Syndecan 1 (plasma cell marker) was positive (**Figure 2**). Based on these findings we made a diagnosis of early stage IPSID. Serum alpha heavy chain levels were not

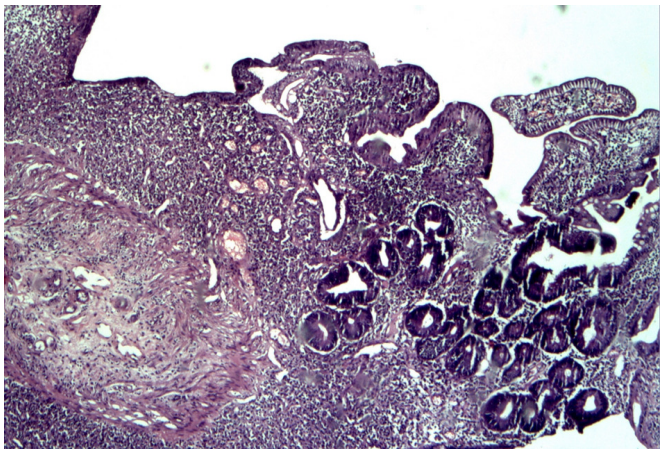

Figure 1: Photomicrograph showing a dense mucosal lymphocytic infiltrate with significant crypt loss and villous blunting (hematoxylin and eosin, 200X)



Figure 2: Photomicrograph showing the mucosal infiltrate staining positively for Syndecan-1 (CD138) immunohistochemistry (avidin biotin technique, 200X)