septum (sensitivity 96%, specificity 100%) and rectal infiltration (sensitivity 92%, specificity 66%).[19]

RAGESH BABU THANDASSERY[1],
SAROJ KANT SINHA[1],
THAKUR DEEN YADAV[2],
ANIL D GALLE[1], KIM VAIPHEI[3],
KARTAR SINGH[1].

Correspondence: Dr. Ragesh Babu Thandassery, Departments of Gastroenterology[1], General Surgery[2] and Histopathology[3], Postgraduate Institute of Medical Education and Research. Chandigarh- 160012, India.
Email: doc.ragesh@gmail.com

References

1. Olive DL, Schwartz LB. Endometriosis. *N Engl J Med*. 1993;**328**:1759–69.
2. De Ceglie A, Bilardi C, Blanchi S, Picasso M, Muzio MD, Trimarchi A, et al. Acute small bowel obstruction caused by endometriosis: a case report and review. *World J Gastroenterol*. 2008;**14**:3430–4.
3. Remorgida V, Ferrero S, Fulcheri E, Ragni N, Martin DC. Bowel endometriosis: presentation, diagnosis, and treatment. *Obstet Gynecol Surv*. 2007;**62**:461–70.
4. Chapron C, Fauconnier A, Vieira M, Barakat H, Dousset B, Pansini V, et al. Anatomical distribution of deeply infiltrating endometriosis: surgical implications and proposition for a classification. *Hum Reprod*. 2003;**18**:157–61.
5. Paksoy M, Karabicak I, Ayan F, Aydogan F. Intestinal obstruction due to rectal endometriosis. *Mt Sinai J Med*. 2005;**72**:405–8.
6. Orbuch IK, Reich H, Orbuch M, Orbuch L. Laparoscopic treatment of recurrent small bowel obstruction secondary to ileal endometriosis. *J Minim Invasive Gynecol*. 2007;**14**:113–5.
7. Jubanyik KJ, Comite F. Extrapelvic endometriosis. *Obstet Gynecol Clin North Am*. 1997;**24**:411–40.
8. Anaf V, El Nakadi I, Simon P, Van de Stadt J, Fayt I, Simonart T, et al. Preferential infiltration of large bowel endometriosis along the nerves of the colon. *Hum Reprod*. 2004;**19**:996–1002.
9. Wong LS, Mahendrakumar R, Bullen BR. Small-bowel endometriosis masquerading as pancreatitis. *J R Soc Med*. 1999;**92**:17–8.
10. Slavin RE, Krum R, Van Dinh T. Endometriosis-associated intestinal tumors: a clinical and pathological study of 6 cases with a review of the literature. *Hum Pathol*. 2000;**31**:456–63.
11. Bianchi A, Pulido L, Espín F, Hidalgo LA, Heredia A, Fantova MJ, et al. Intestinal endometriosis. Current Status. *Cir Esp*. 2007;**81**:170–6.
12. de Bree E, Schoretsanitis G, Melissas J, Christodoulakis M, Tsiftsis D. Acute intestinal obstruction caused by endometriosis mimicking sigmoid carcinoma. *Acta Gastroenterol Belg*. 1998;**61**:376–8.
13. Mussa FF, Younes Z, Tihan T, Lacy BE. Anasarca and small bowel obstruction secondary to endometriosis. *J Clin Gastroenterol*. 2001;**32**:167–71.
14. Remorgida V, Ragni N, Ferrero S, Anserini P, Torelli P, Fulcheri E. The involvement of the interstitial Cajal cells and the enteric nervous system in bowel endometriosis. *Hum Reprod*. 2005;**20**:264–71.
15. Kaufman LC, Smyrk TC, Levy MJ, Enders FT, Oxentenko AS. Symptomatic intestinal endometriosis requiring surgical resection: clinical presentation and preoperative diagnosis. *Am J Gastroenterol*. 2011;**106**:1325–32.
16. Garry R. Electrosurgical resection of endometriosis. In: Redwine DB (ed). Surgical Management of Endometriosis. London: Taylor & Francis; 2004:71–85.
17. Bazot M, Darai E. Sonography and MR imaging for the assessment of deep pelvic endometriosis. *J Minim Invasive Gynecol*. 2005;**12**:178–85.
18. Biscaldi E, Ferrero S, Fulcheri E, Ragni N, Remorgida V, Rollandi GA. Multislice CT enteroclysis in the diagnosis of bowel endometriosis. *Eur Radiol*. 2007;**17**:211–9.
19. Roseau G, Dumontier I, Palazzo L, Chapron C, Dousset B, Chaussade S, et al. Rectosigmoid endometriosis: endoscopic ultrasound and clinical implications. *Endoscopy*. 2000;**32**:525–30.

Non-traumatic rupture of malarial spleen

Introduction

Blunt abdominal trauma is the most common cause of splenic rupture. Non-traumatic splenic rupture is rare and occurs in a diseased spleen. Among the non-traumatic causes, haematological malignancy is the leading cause of splenic rupture; others being infection, malignancy, vascular, genetic or haematological disorders.[1] However, in countries where malaria is endemic, it outnumbers haematological malignancy as the leading cause of splenic rupture.[1,2] We report a case of non-traumatic rupture of the spleen with a large subcapsular splenic haematoma and haemoperitoneum in a patient suffering from acute malaria.

Case report

A 27-year-old man presented to the emergency department with pain in the left hypochondrium and distention of the abdomen. The patient gave a history of intermittent high-grade fever with chills and rigor for the past 4 days. There was no

history of any trauma or abnormal bleeding tendency. The patient was receiving antimalarial treatment for diagnosed Plasmodium vivax infection (seen on peripheral blood smear), which was prescribed to him by a local physician. On clinical examination, the patient had pallor and tachycardia with a normal blood pressure and local tenderness in the left hypochondrium, but there was no abdominal guarding or rigidity. Blood/serum profile showed dimorphic anaemia with increased serum bilirubin level (2.7 mg/dL) and low platelet count (90,000/dL). The Widal test was negative. Ultrasonography (USG) revealed a large, subcapsular splenic haematoma with free fluid in the abdomen consistent with haemoperitoneum. Computed tomography (CT) scan confirmed the presence of a large, subcapsular splenic haematoma (hyperdense on non-contrast CT scan, 70 Hounsfield units) with extension into the perisplenic and left subdiaphragmatic region) with free fluid in the abdomen (**Figures 1–3**). The patient underwent an urgent splenectomy and the histopathology

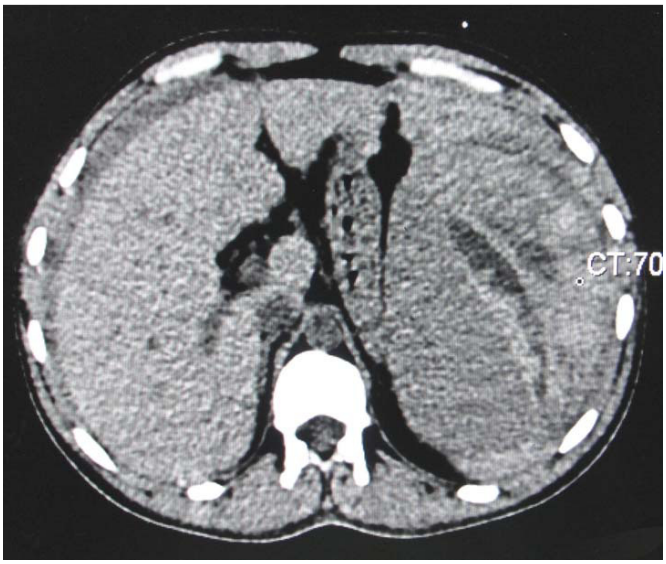

Figure 1: Non-contrast axial section of the upper abdomen showing a large, hyperdense subcapsular splenic haematoma (HU-70) with areas of liquefaction and mild perihepatic free fluid.

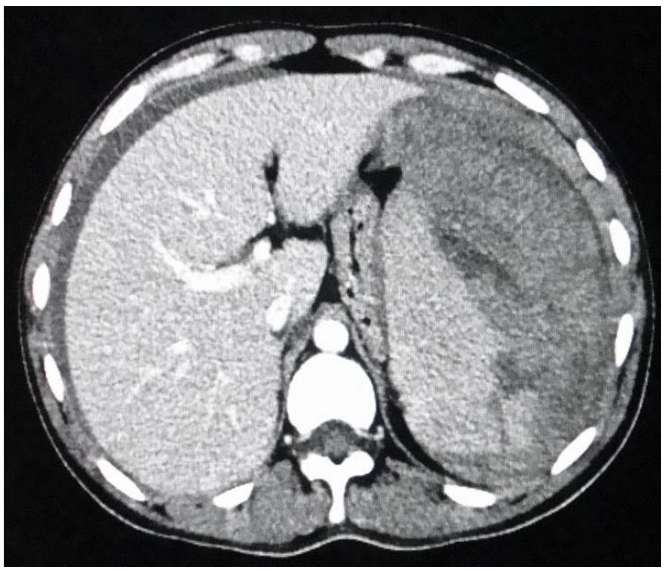

Figure 2: Contrast-enhanced axial section showing non-enhancing, subcapsular haematoma producing mass effect on the normally enhancing spleen. A focal laceration in the lateral surface of the spleen can also be noted.

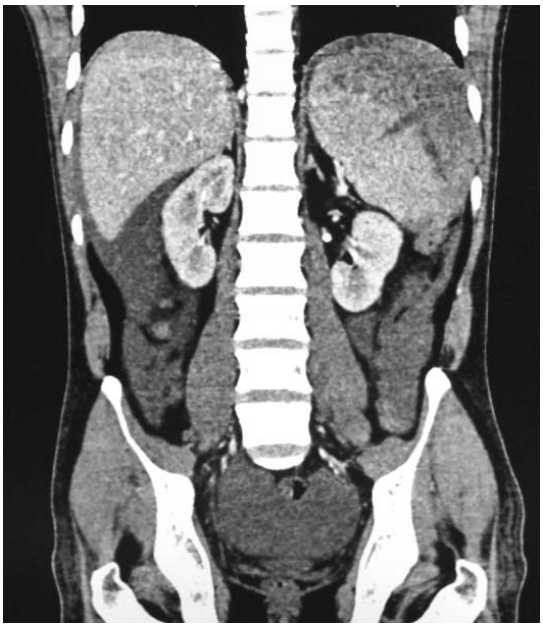

Figure 3: Contrast-enhanced coronal scan showing the rent in the superolateral surface of the spleen with a large subcapsular haematoma with associated haemoperitoneum.

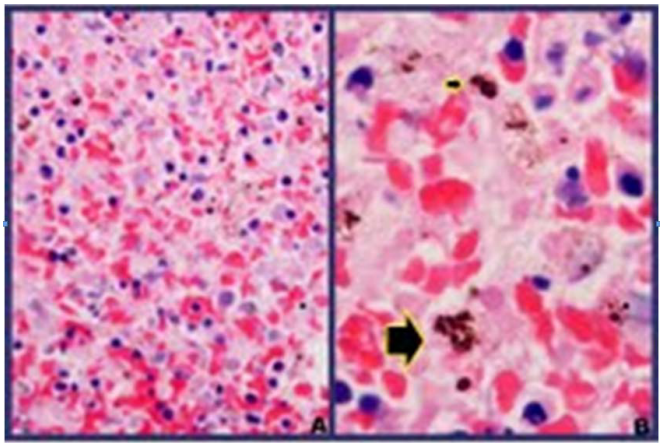

Figure 4: Microscopic examination of the spleen (H&E stain) showing (A) splenic sinusoids with large areas of haemorrhage and some brownish black pigment (X40). (B) The pigment is better seen on higher magnification which is brown black, non-refractile and is seen in sinusoidal macrophages (large arrow) and red blood cells (small arrow). The pigment was negative for iron stains (figures not shown), thus confirming it as malarial pigment.

report revealed the presence of malarial pigment in the ruptured spleen (**Figure 4**).

Discussion

Malaria is a parasitic infection caused by Plasmodium species. In India, P. vivax accounts for approximately 55% of cases whereas 40%–42% of cases are caused by P. falciparum which is most frequently associated with severe complicated malaria.[1] Infections by other two species are often subclinical and associated with fewer complications. However, splenic complications are commonly associated with non-falciparum species especially P. vivax. They occur in up to 2% of cases.[3,4] Patients may present with left hypochondriac pain which may be due to infarct in an enlarged spleen, trauma to an enlarged spleen and rarely rupture of the spleen. Most cases of splenic rupture occur during acute infection. Although there is considerable splenomegaly in chronic malaria, rupture is uncommon as excessive fibrosis acts as a protective barrier against rupture. In cases with acute disease, there is rapid enlargement and stretching of splenic capsule secondary to vascular congestion and cellular hyperplasia, and the lack of fibrosis predisposes to splenic rupture. Diagnosis should always be suspected in a patient from an endemic region who presents with rapid onset of hypotension and severe left hypochondrial pain. Abdominal USG is a rapid bedside modality for assessing the severity of splenic rupture, amount of subcapsular and intraperitoneal haematoma. It also helps to exclude other causes which may present with left hypochondrial pain such as left-sided pleural pathology, pancreatitis and renal calculi. In haemodynamically stable patients, CT scan can be performed to delineate the findings and a better assessment of their severity.[2–5]

MADHUKAR DAYAL[1],
RAJU SHARMA[1],
NADARAJAH JEYASEELAN[1],
RITA SOOD[2],
SANDEEP R. MATHUR[3],
SANJEEV CHITRAGAR[3],

Correspondence: Dr Raju Sharma
Department of Radiodiagnosis[1], Medicine[2], and Pathology[3], AIIMS, New Delhi - 110029, India
Email: raju152@yahoo.com

References

1. Gupta N, Lal P, Vindal A, Hadke NS, Khurana N. Spontaneous rupture of malarial spleen presenting as hemoperitoneum: a case report. *J Vector Borne Dis*. 2010;**47**;119–20.
2. Choudhury J, Uttam KG, Mukhopadhyay M. Spontaneous rupture of malarial spleen. *Indian Pediatr*. 2008;**45**:327–8.
3. Yagmur Y, Kara IH, Aldemir M, Büyükbayram H, Tacyildiz IH, Keles C. Spontaneous rupture of malarial spleen: two case reports and review of literature. *Crit Care*. 2000;**4**:309–13.
4. Tauro LF, Maroli R, D'Souza CR, Hedge BR, Shetty SR, Shenoy D. Spontaneous rupture of the malarial spleen. *Saudi J Gastroenterol*. 2007;**13**:163–7.
5. Correia M, Amonkar D, Audi P, Kudchadkar S. Spontaneous rupture of a malarial spleen—a case report and review of literature. *Internet J Surg*. 2010;23. Doi:10.5580/1aa8.

Enteral stenting using the rendezvous technique

Introduction

We report a rare case of management of metastatic carcinoma colon with postoperative recurrence in a patient who had presented with anastomotic stricture and acute intestinal obstruction. She underwent combined percutaneous fluoroscopic insertion of guidewire and rendezvous insertion of fully covered self-expanding metallic stent (SEMS) and achieved palliation.

Case report

A 67-year-old woman, a known case of carcinoma colon (post-right hemicolectomy), presented with a history of jaundice for the past 6 months due to lymph node metastases at the porta hepatis. Percutaneous stenting (Luminexx Bard) of the right anterior, right posterior and left biliary system was done (as endoscopic retrograde cholangiopancreatigraphy failed) to palliate jaundice. No further treatment was opted because of her poor performance status. The patient was largely aymptomatic for 6 months after which she presented with acute intestinal obstruction (**Figure 1**) due to recurrence of tumour at the anastomotic site. After initial resuscitation, stenting was