Tropical Gastroenterology 2011;32(2):157–158

Granulomatous hepatitis from disseminated *Mycobacterium bovis* infection: shift of an intended local towards a detrimental systemic infection

An 80-year-old male presented with worsening fever, chills and night sweats 10 days after he received his fifth intravesical BCG instillation for his recurrent low-grade transitional cell carcinoma of the bladder. Review of systems was remarkable for mild dysuria and hematuria. Physical examination revealed a temperature of 102°F. He had no hepatosplenomegaly or lymphadenopathy. Laboratory evaluation was significant for leukopenia (3000/μL) and elevated LFTs (alkaline phosphatase (ALP)-378 U/L, AST-70 U/L, ALT-26 U/L). Prior to presentation, isoniazid was initiated by his urologist for presumptive BCG infection. Rifampin and levofloxacin were added upon admission to the hospital. Routine blood and urine cultures did not yield any pathogens and the results of serologic tests to assess virus, bacteria, and fungus were negative. Chest X-ray was unremarkable but the chest-CT revealed diffuse, miliary nodular infiltrates suspicious for *Mycobacterium* infection (**Figure 1**). A USG-guided liver biopsy was performed for a persistently elevated ALP and revealed granulomatous hepatitis with non-caseating epithelioid granulomas (**Figure 2**). Gram stain, AFB, GMS, FITE and immunohistochemical stains did not detect any organisms and tissue culture was negative. Worsening pancytopenia prompted a bone marrow biopsy that revealed multiple large granulomas. The patient gradually improved and his fever subsided within several days of anti-tuberculous therapy. Liver abnormalities resolved during the following week. He completed a 6-month course of isoniazid and rifampin, and continues to do well at 1-year follow-up.

Figure 1: Computed tomography of the chest showing multiple, bilateral, small pulmonary nodules

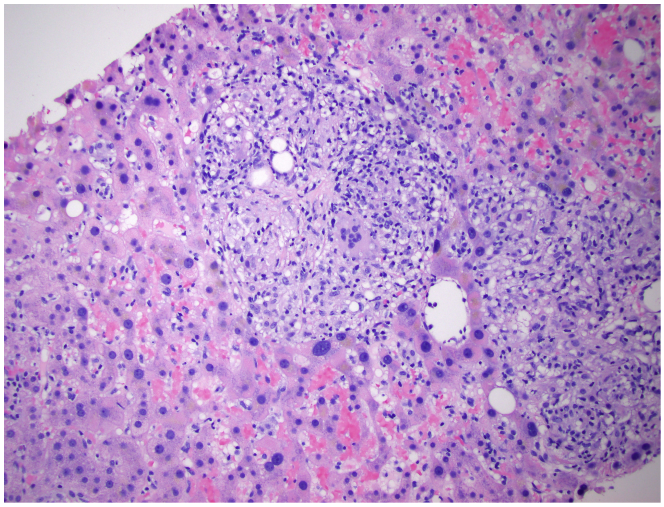

Figure 2: Histopathology of liver biopsy specimen showing granulomatous hepatitis with multinucleated-giant cell epitheliod granulomas

Intravesical BCG is an effective treatment for superficial bladder cancer with a success rate varying between 63 and 100%.[1,2] Minor complications including hematuria, cystitis, fever (<38.5°C) and malaise are quite common, whereas major complications such as both local (granulomatous prostatitis, epididymo-orchitis, ureteral obstruction, bladder contracture) and systemic reactions (fever >39.5°C, sepsis, pancytopenias, granulomatous hepatitis and pneumonitis) occur occasionally.[2-5]

BCG complications generally result from contiguous and hematogenous spread of intravesical mycobacteria through inflamed and/or disrupted urothelium most frequently caused by traumatic catheterization, bladder perforation, or by extensive tumor resection.[2-5] Granulomatous hepatitis is a rare (<0.4%) and serious complication after BCG instillation, with unclear pathogenesis.[2-4] It has been considered a hypersensitivity reaction to BCG based on negative staining and cultures of liver tissue.[2-4] However, cases have been reported in which mycobacteria were present on staining and mycobacterial DNA was detected in liver tissue suggesting a liver infection after hematogenous dissemination of BCG, rather than hypersensitivity.[4]

There have been no prospective studies to evaluate the optimal treatment for BCG infection.[2-5] In severe systemic cases, some data supports the administration of three anti-tuberculous drugs including isoniazid, rifampin and ethambutol for at least

6 months.[2-4] The addition of corticosteroids during initial therapy may assist in a faster resolution of inflammatory complications.[2-4]

TARUN RUSTAGI[1]
MRIDULA RAI[1]
TODD J. ALEKSHUN[2]

Correspondence: Dr. Tarun Rustagi
Department of Internal Medicine,[1]
University of Connecticut
Farmington, Connecticut, CT 06032, USA
Division of Hematology-Oncology,[2] Hartford Hospital
Hartford, Connecticut, USA.
Email: trustagi@resident.uchc.edu

References

1. Witjes JA, vd Meijden AP, Debruyne FM. Use of intravesical bacillus Calmette-Guerin in the treatment of superficial transitional cell carcinoma of the bladder: an overview. *Urol Int*. 1990;**45**:129–36.
2. Trevenzoli M, Cattelan AM, Marino F, Sasset L, Donà S, Meneghetti F. Sepsis and granulomatous hepatitis after bacillus Calmette-Guerin intravesical installation. *J Infect*. 2004;**48**:363–4.
3. Lamm DL, van der Meijden PM, Morales A, Brosman SA, Catalona WJ, Herr HW, et al. Incidence and treatment of complications of bacillus Calmette-Guerin intravesical therapy in superficial bladder cancer. *J Urol*. 1992;**147**:596–600.
4. Leebeek FW, Ouwendijk RJ, Kolk AH, Dees A, Meek JC, Nienhuis JE, et al. Granulomatous hepatitis caused by Bacillus Calmette-Guerin (BCG) infection after BCG bladder instillation. *Gut*. 1996;**38**:616–8.
5. Gonzales OY, Musher DM, Brar I, Furgeson S, Boktour MR, Septimus EJ, et al. Spectrum of bacillus Calmette-Guerin (BCG) infection after intravesical BCG immunotherapy. *Clin Infect Dis*. 2003;**36**:140–8.