its distal most location in the gut and thereby bearing the brunt of gravity too.

Till date no case of EDS with a predominant abdominal presentation and specifically with recurrent intestinal obstruction due to a redundant rectum, has been reported, though surgical complications of EDS have been described.[10] In face of paucity of literature and our greater experience with posterior sagittal anorectoplasty, it was considered worthwhile to resect the redundant rectum through posterior sagittal approach in order to straighten its course. Some authors do advise supplementation of vitamin C in the patients with type VI EDS, considering it to be caused by dysfunctional lysyl hydroxyl enzyme.[1]

In short, although EDS is a rare condition, its possibility should be kept in mind in a child presenting with multiple hernias. The parents should also be screened for the signs of this disease so that genetic counseling can be done for subsequent pregnancies.

JOHN RATAN[1]
GHAZI MUKATTASH[1]
GOVINDRAJAN HARIHARAN[1]
BALU SAVLA[1]
SHAH MASABAT SALEEM[1]
SAMIR MORSY HEGAB[1]

Correspondence: Dr. John Ratan
Department of Pediatric Surgery,[1]
Maternity and Children Hospital, Najran,
Kingdom of Saudi Arabia
Email: drjohnratan@yahoo.co.in

References

1. Shashikiran U, Rastogi A, Gupta RP, Sabir M. Ehler-Danlos syndrome type VI variant presenting with recurrent respiratory infections and responding to high dose vitamin C. *J Assoc Physicians India*. 1999;**47**:554–5.
2. Prockop DJ, Ala-kokko L. Inherited disorders of connective tissue. In: Kasper DL, Braunwald E, Fauci AS, Hauser SL, Longo DL, Jameson JL, editors. *Harrison's Principle of Internal Medicine. New York: Mc Graw Hill Medical Publishing Division*; 2005.p.2324–30.
3. Beighton P, De Paepe A, Steinmann B, Tsipouras P, Wenstrup RJ. Ehlers-Danlos Syndromes: revised nosology. Villefranche, 1997. Ehler- Danlos Foundation (USA) and Ehler-Danlos Support Group (UK). *Am J Med Genet*. 1998;**77**:31–7.
4. Yeowell NH, Pinnell SR: The Ehlers-Danlos Syndrome. *Semin Dermatol*. 993;**12**:229.
5. Parikh F, Sivaramakrishnan A, Pai-dhunghat JV. Type VI Ehler Danlos Syndrome. *J Assoc Physicians India*. 2004;**52**:631.
6. Pope FM, Narcisi P, Nicholls AC, Liberman M, Oorthuys JW. Clinical presentations of Ehler Danlos Syndrome type IV. *Arch Dis Child*. 1988;**63**:1016–25.
7. Patel AB, Renge RL. Ehler-Danlos Syndrome. *Indian Pediatr*. 2002;**39**:784–5.
8. Olaosebikan A, Wolf B. Ehlers-Danlos Syndrome in a Zimbabwean child. *Cent Afr J Med*. 1993;**39**:20–2.
9. Nicholls AC, Oliver JE, McCarron S, Harrison JB, Greenspan DS, Pope FM. An exon skipping mutation of a type V collagen gene (COL5A1) in Ehlers-Danlos syndrome. *J Med Genet*. 1996;**33**:940–6.
10. McEntyre RL, Raffensperger JG. Surgical complications of Ehler-Danlos syndrome in children. *J Pediatr Surg*. 1977;**12**:531–5.

Management of peristomal pyoderma gangrenosum - two different approaches for the same clinical problem

Introduction

Peristomal pyoderma gangrenosum (PPG) is a rare condition seen in patients with inflammatory bowel disease. It causes significant morbidity, complicates stomal care and prolongs the duration of treatment. The management of this condition is difficult and requires a multidisciplinary approach involving the gastroenterologist, dermatologist, surgeon, and stomal therapist. We report 2 patients of PPG with severe ulcerative colitis. Through these cases we attempt to illustrate the varying response these patients may have to high dose steroid therapy which may necessitate an earlier recourse to completion proctectomy or colectomy.

Case 1

A twenty-one year old man, a known case of chronic steroid-dependant ulcerative colitis, underwent subtotal colectomy with end ileostomy and a Hartmann's rectal pouch procedure. Following surgery, the steroids were gradually tapered over a period of 1 month. Four months following complete withdrawal of steroids, the patient developed a painful peristomal ulcer (6 cm by 5 cm) (**Figure 1a**). There were no constitutional symptoms, hematochezia, or extra-intestinal manifestations.

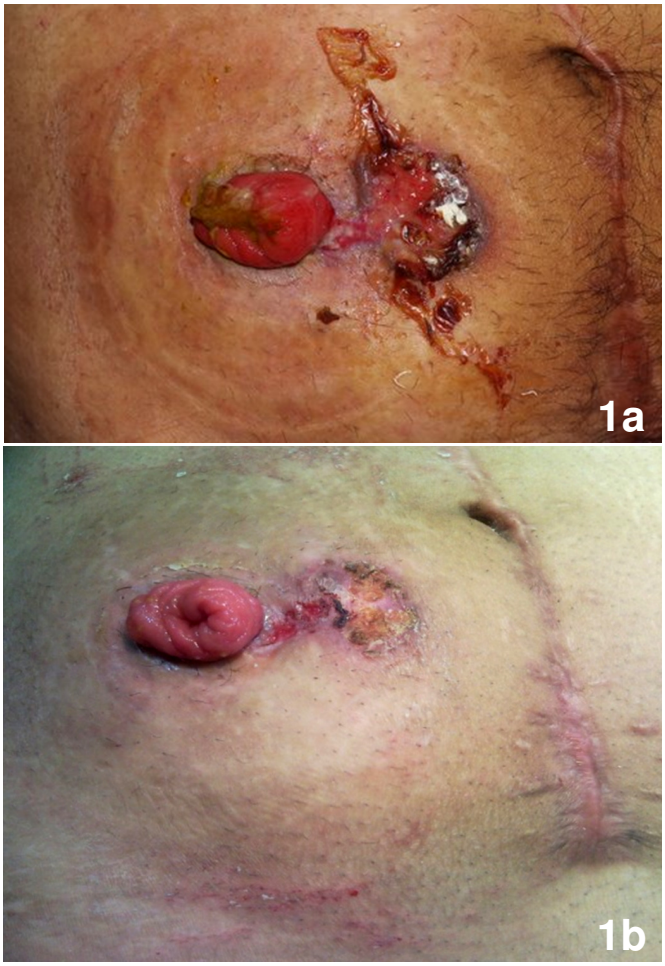

Figure 1: (a) Peristomal ulceration at presentation and (b) 1 week after steroid treatment

The skin biopsy done showed surface ulceration with dense mixed inflammatory infiltrate (predominantly neutrophils), and evidence of small vessel vasculitis, with no microorganisms seen on special stains which was consistent with the clinical diagnosis of pyoderma gangrenosum (**Figures 2a & 2b**). The patient was re-started on oral steroids (prednisolone 40 mg per day). Within 1 week of starting steroids, the lesions showed signs of healing (**Figure 1b**). After 1 month of steroid treatment, the ulcer had completely healed. This patient subsequently underwent completion proctectomy with an ileal J-pouch anal anastomosis (double stapled technique) and a covering loop ileostomy. The patient is now awaiting ileostomy closure and is on regular follow up at 2 weekly intervals. Barring an episode of adhesive intestinal obstruction which was managed conservatively, the patient is doing well, the steroids have been tapered, and all operative wounds have healed well with no recurrence of the ulcer.

Case 2

Three months following subtotal colectomy for a severe acute exacerbation of ulcerative colitis (refractory to intensive steroid regimen), a 35-year old lady presented with a painful ulcer (8 cm by 4 cm) around the ileostomy (**Figure 3a**). She had high grade fever, decreased appetite and complained of increased rectal bleeding. Proctoscopic examination revealed an inflamed rectal mucosa with ulcerations and pseudopolyps. She had anemia and a raised erythrocyte sedimentation rate (ESR). A skin biopsy showed features consistent with a diagnosis of pyoderma gangrenosum. A few days later she developed another similar lesion on her shin. She was started on prednisolone (40 mg per day) and received 3 pulses of dexamethasone (100 mg per day for 5 days every 4 weeks). Following initial improvement, the peristomal lesion subsequently worsened with enlargement in size (13 cm by 17 cm) and appearance of a new lesion (**Figure 3b**). There was difficulty in applying ileostomy appliance, and the ileostomy effluent was managed by frequent changes of pads. She also had persistent rectal bleeding despite being on systemic

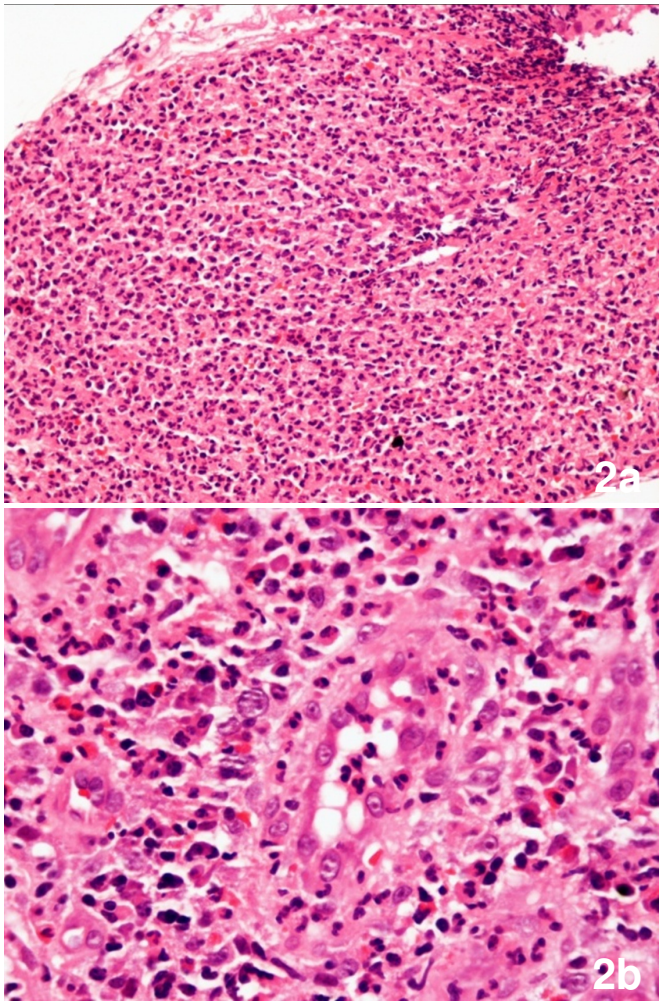

Figure 2: (a) Skin biopsy showing dense mixed inflammatory infiltrate predominantly by neutrophils with small vessel vasculitis (H&E stain; X 40) and (b) shows mixed inflammation predominantly by neutrophils and evidence of small vessel vasculitis (H&E stain; X 400).

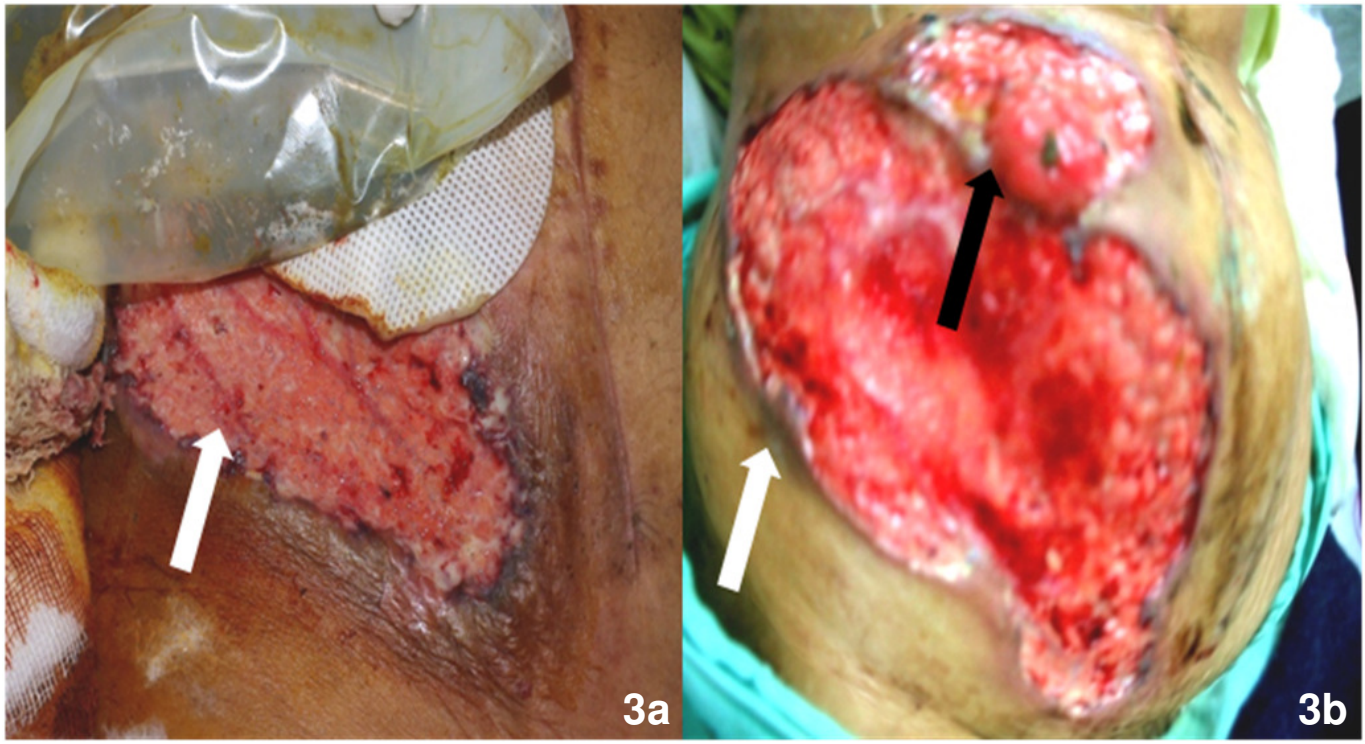

Figures 3: (a) The white arrow points out the peristomal skin ulceration due to pyoderma gangrenosum. Despite dexamethasone pulse therapy, the ulceration markedly increased with appearance of a new lesion (b). The black arrow points at the end ileostomy.

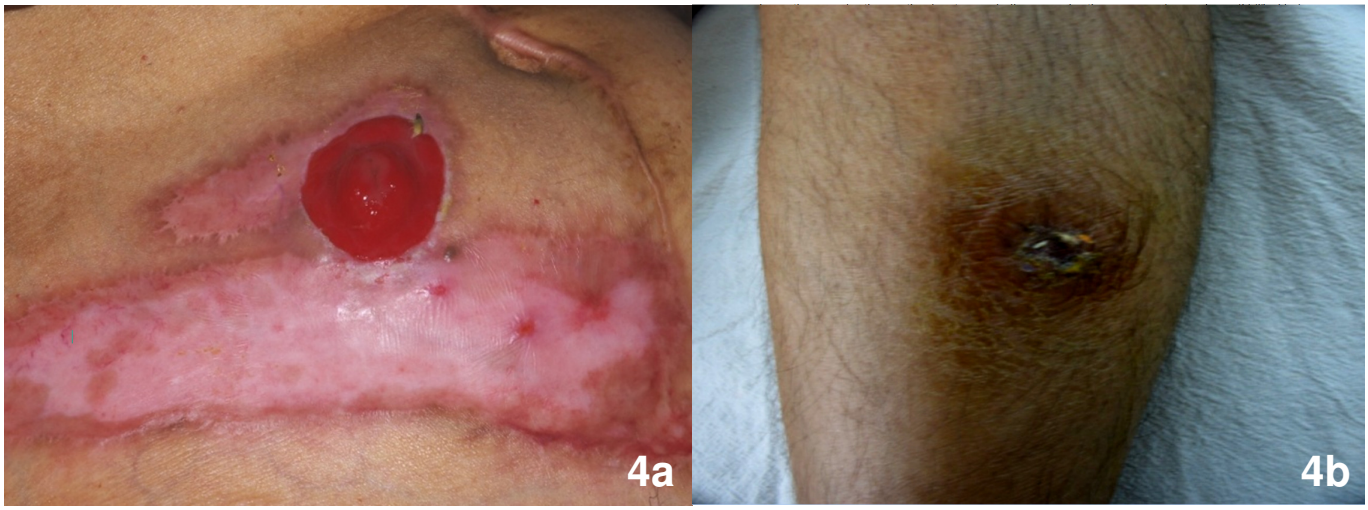

Figure 4: (a) The healed peristomal and (b) shin pyoderma gangrenosum following surgery

steroids and topical mesalamine treatment. In view of a relapse of the pyoderma gangrenosum, and a negligible response to high dose steroids, she underwent a completion proctectomy with an ileal J-pouch anal anastomosis (double stapled technique) and a covering loop ileostomy. Within a month of the operative procedure, the skin lesions (both peristomal and shin) healed completely (**Figures 4a & 4b**). She subsequently underwent closure of the ileostomy. At the last follow-up, 3 years following her ileostomy closure, the patient was doing well with good pouch function and no recurrence of the skin lesions.

Discussion

Peristomal pyoderma gangrenosum (PPG) is a disabling condition in patients with a stoma. The lesion begins as small erythematous papules that rapidly spread concentrically, coalesce and subsequently develop central ulceration and necrosis. The mature lesions have well-defined, undermined, violaceous border and are very painful.[1]

The exact incidence of PPG is not known. We diagnosed PPG in 2 of the 250 patients who underwent surgery for inflammatory bowel disease in our unit. It is possible that the

incidence of PPG is higher than reported because PPG is often under-diagnosed or misdiagnosed as stitch abscess, contact dermatitis, irritation from leaking feces or urine, extension of underlying Crohn's disease or a wound infection. A high index of suspicion and familiarity with the appearance of the lesion is needed to make a diagnosis.

The cause of PPG is still debated. The name pyoderma gangrenosum reflects the historical view of the disease as an infectious process, but the characteristic lesions are sterile. Most patients relate the development of the skin lesions to trauma in the peristomal area. It has been suggested that in patients with IBD, the development of PPG may reflect the severity of intestinal disease.[2] The PPG lesions in our first patient appeared after the withdrawal of steroids. The second patient had undergone subtotal colectomy for an acute exacerbation that was refractory to intensive medical management with steroids. The subsequent appearance and worsening of pyoderma gangrenosum in this patient, correlated with worsening of the disease in rectal stump (increased bleeding per rectum, inflamed rectal mucosa with ulcerations, anemia and raised ESR).

The time to onset for PPG is variable and may range from a few months to up to many years. The rapidity of progression is considered to be the hallmark of the disease.[3] Our patients developed the lesions 3-4 months following creation of the ileostomy and showed rapid progression. The lesions made stoma care very difficult and labor intensive. In the second patient, the peristomal lesion was so large that the stomal appliance could not be applied and the local care of the wound and stoma was done by frequent change of dressing pads.

The best therapy for PPG is not known. Topical treatment with steroids, antibiotics or other wound care agents have been described.[4] However, these modalities may not be suitable for larger lesions and have no impact on the underlying intestinal disease.

The other options are to treat the underlying active inflammation in the gastrointestinal tract. A few reports describe the use of systemic therapy with high dose steroids, antibiotics, dapsone, cyclosporine, and infliximab.[5-7] Steroid pulse therapy has also been reported to be effective in some cases.[8] We managed our first patient with systemic steroids and he showed a good clinical response. The second patient was initially managed with prednisolone (40 mg/day) and 3 pulses of dexamethasone pulse therapy (100 mg/day for 5 days every 4 weeks). However, her skin lesions were refractory to this treatment. Infliximab was not considered because of its high cost.

The surgical treatment options for PPG include stoma revision and relocation but these may have failure rates as high as 40%-100%.[9] Removal of the actively diseased intestinal segment may be a treatment option in these patients and may result in healing of the skin lesion.[10] The PPG in our second patient were refractory to steroids but showed prompt healing following surgical removal of the diseased rectum.

AMIT JAVED[1]
SUJOY PAL[1]
VINEET AHUJA[2]
M RAMAM[3]
KIRAN CHIKKANAHALLI SUBBARAO[4]
PEUSH SAHNI[1]
TUSHAR KANTI CHATTOPADHYAY[1]

Correspondence: Dr. Amit Javed
Departments of Gastrointestinal Surgery,1
Gastroenterology,2 Dermatology,3 and Pathology,4
All India Institute of Medical Sciences,
New Delhi - 110029, India
Email: javedamitdr@gmail.com

References

1. Callen JP: Pyoderma gangrenosum. *Lancet*. 1998;**351**:581–5.
2. Hughes AP, Jackson JM, Callen JP: Clinical features and treatment of peristomal pyoderma gangrenosum. *JAMA*. 2000;**284**:1546–8.
3. Holt PJ: The current status of pyoderma gangrenosum. *Clin Exp Dermatol*. 1979;**4**:509–16.
4. Nybaek H, Olsen AG, Karlsmark T, Jemec GB: Topical therapy for peristomal pyoderma gangrenosum. *J Cutan Med Surg*. 2004;**8**:220–3.
5. Funayama Y, Kumagai E, Takahashi K, Fukushima K, Sasaki I: Early diagnosis and early corticosteroid administration improves healing of peristomal pyoderma gangrenosum in inflammatory bowel disease. *Dis Colon Rectum*. 2009;**52**:311–4.
6. Poritz LS, Lebo MA, Bobb AD, Ardell CM, Koltun WA: Management of peristomal pyoderma gangrenosum. *J Am Coll Surg*. 2008;**206**:311–5.
7. Sapienza MS, Cohen S, Dimarino AJ: Treatment of pyoderma gangrenosum with infliximab in Crohn's disease. *Dig Dis Sci*. 2004;**49**:1454–7.
8. Galun E, Flugelman MY, Rachmilewitz D: Pyoderma gangrenosum complicating ulcerative colitis: successful treatment with methylprednisolone pulse therapy and dapsone. *Am J Gastroenterol*. 1986;**81**:988–9.
9. Kiran RP, O'Brien-Ermlich B, Achkar JP, Fazio VW, Delaney CP: Management of peristomal pyoderma gangrenosum. *Dis Colon Rectum*. 2005;**48**:1397–403.
10. Talansky AL, Meyers S, Greenstein AJ, Janowitz HD: Does intestinal resection heal the pyoderma gangrenosum of inflammatory bowel disease? *J Clin Gastroenterol*. 1983; **5**:207–10.