change they tend to progress rapidly.[15] Rapid progression is not a feature of FIF and to the best of our knowledge this is the first ever reported case of FIF which presented with rapid progression in size, raising suspicion of malignant teratoma. Moreover, non visualization of vertebral column on X-ray further decreased the suspicion of the possibility of FIF. FIF is differentiated from teratoma by the presence of an axial skeleton and organoid formations within the mass;[1] however, maturation of all organs may not be parallel, with some being incompletely developed. Although X-ray and USG are helpful in diagnosing FIF,[7] the diagnostic yield is greatly increased by CT and MRI. It is even possible to diagnose it prenatally. The treatment of FIF is by resection, as was done in the present case.

VIVEK AGRAWAL [1]
MOHIT KUMAR JOSHI[1]
SUNIL GOMBER[2]

Correspondence: Dr. Vivek Agrawal
Departments of Surgery[1] and Pediatrics[2]
University College of Medical Sciences & Guru Teg Bahadur Hospital, New Delhi
Email: vivekgtbh@gmail.com

References

1. De Lagausie P, De Napoli Cocci S, Stempfle N, Truong QD, Vuillard E, Ferkadji L, et al. Highly differentiated teratoma and fetus-in-fetu: a single pathology? *J Pediatr Surg*. 1997;**32**:115–6.
2. Kahloul N, Adouani M, Khattat N, Allani H, Krichen I, Zakhama A, et al. Fetus in fetu: a case report. *Arch Pediatr*. 2010;**17**:249–52.
3. Khalifa NM, Maximous DW, Abd-Elsayed AA. Fetus in fetu: a case report. *J Med Case Reports*. 2008;**2**:2.
4. Kim JW, Park SH, Park SS, Wang KC, Cho BK, Kim SY et al. Fetus-in-fetu in the cranium of a 4-month-old boy: histopathology and short tandem repeat polymorphism-based genotyping. Case report. *J Neurosurg Pediatr*. 2008;**1**:410–4.
5. Arlikar JD, Mane SB, Dhende NP, Sanghavi Y, Valand AG, Butale PR. Fetus in fetu: two case reports and review of literature. *Pediatr Surg Int*. 2009;**25**:289–92.
6. Marnet D, Vinchon M, Kerdraon O, Joriot S, Chafiotte C, Dhellemmes P. Antenatal diagnosis of a third ventricular mass: fetus in fetu or teratoma? *Childs Nerv Syst*. 2008;**24**:887–91.
7. Balogun BO, Bankole MA, Akinola RA, Akintomide TE, Olayiwola B, Jinadu FO. Fetus-in-fetu. *Afr J Paediatr Surg*. 2008;**5**:93–5.
8. Eng HL, Chuang JH, Lee TY, Chen WJ. Fetus in fetu: a case report and review of the literature. *J Pediatr Surg*. 1989;**24**:296–9.
9. Abdur-Rahman LO, Abdul-Kadir AY, Rahman AG. Fetus-in-fetu in a 6-month-old. *Afr J Paediatr Surg*. 2008;**5**:96–8.
10. Mohan H, Chhabra S, Handa U. Fetus-in-fetu: a rare entity. *Fetal Diagn Ther*. 2007;**22**:195–7.
11. Karaman I, Erdoðan D, Ozalevli S, Karaman A, Cavuþoðlu YH, Aslan MK, et al. Fetus in fetu: A report of two cases. *J Indian Assoc Pediatr Surg*. 2008;**13**:30–2.
12. Magnus KG, Millar AJ, Sinclair-Smith CC, Rode H. Intrahepatic fetus-in-fetu: a case report and review of the literature. *J Pediatr Surg*. 1999;**34**:1861–4.
13. Kajbafzadeh AM, Baharnoori M. Fetus in fetu. *Can J Urol*. 2006;**13**:3277–8.
14. Daga BV, Chaudhary VA, Ingle AS, Dhamangaokar VB, Jadhav DP, Kulkarni PA. Double fetus-in-fetu: CT scan diagnosis in an adult. *Indian J Radiol Imaging*. 2009;**19**:216–8.
15. Taori K, Rathod J, Deshmukh A, Sheorain VS, Jawale R, Sanyal R et al. Primary extragonadal retroperitoneal teratoma in an adult. *Br J Radiol*. 2006;**79**:e120–2.

The quest for a needle in a haystack: report of an unusual case

Introduction

Metallic intra-abdominal foreign bodies are an uncommon cause of abdominal pain. They are often diagnosed serendipitously. Foreign bodies have been retrieved from a myriad of locations. However, intra-pancreatic location of such foreign bodies is distinctly unusual. We report the successful retrieval of two metallic pins which were found embedded in the pancreas.

Case Report

A 19 year old boy presented with persistent epigastric pain radiating to the back, of three months duration. The patient denied history of recent jaundice, abdominal trauma and alcohol ingestion, altered bowel habits or recent weight loss. Clinical examination was unremarkable. He was initially evaluated with routine blood tests, serum amylase study and ultrasound study of the abdomen, which were normal. CECT abdomen (**Figure 1**) revealed the presence of two linear, hyperdense structures in the region of the lesser sac, abutting the body of the pancreas. Barium meal study (**Figure 2**) clearly delineated the extra-luminal location of the two metallic foreign bodies. He was subsequently taken up for diagnostic laparoscopy. Since the object could not be localised at laparoscopy, a mini laparotomy was done. Intraoperative fluoroscopy and

'mapping' of the lesser sac and pancreas aided in the detection of the intra-pancreatic foreign bodies. Two thin (2 mm) metallic pins, each 2 cm long, were found to be embedded in the body of the pancreas at right angles to each other (**Figure 3**). They could be retrieved with minimal trauma to the pancreatic tissue. Postoperative period was uneventful and the patient was discharged on the seventh postoperative day. The patient was followed up at 3 months and he is doing fine.

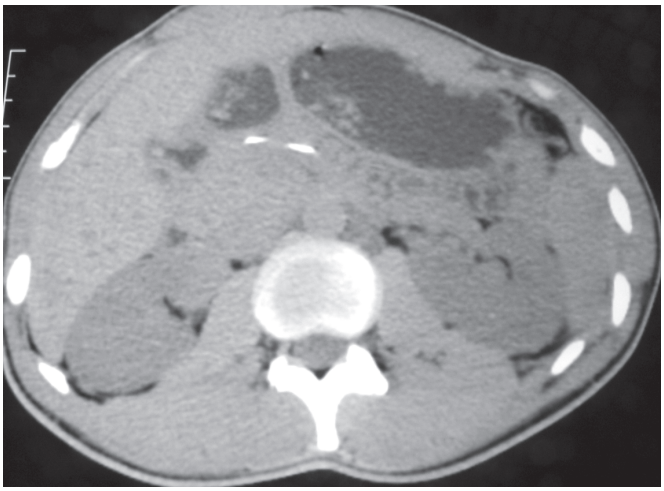

Figure 1: Axial contrast enhanced CT image show two, linear hyperdense structures in the region of the lesser sac, abutting the body of the pancreas

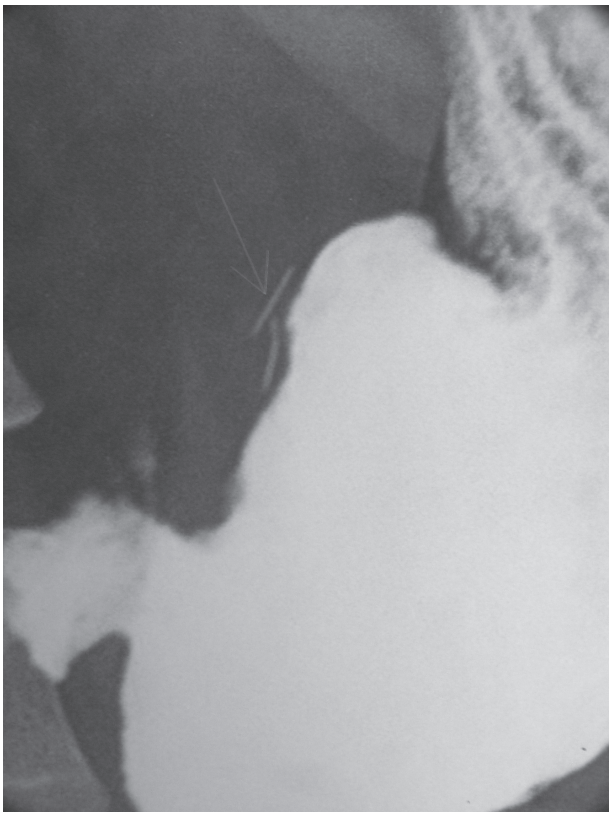

Figure 2: Barium meal image (Right Anterior Oblique view) shows two radioopaque foreign bodies, located extraluminally, in relation to the lesser curvature of the stomach

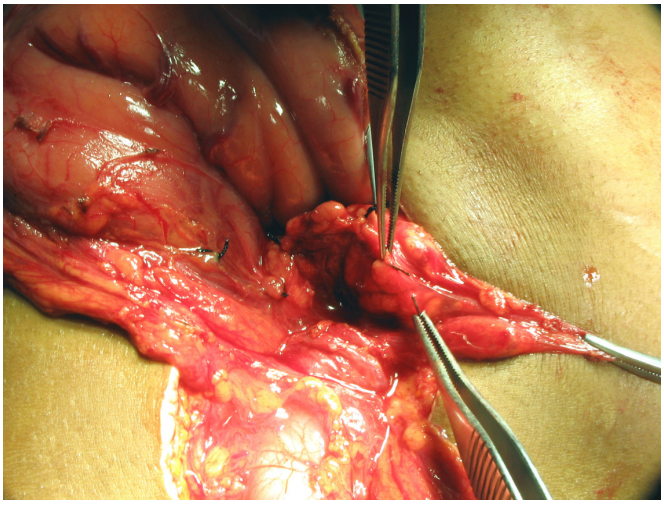

Figure 3: Peroperative photograph shows two metallic pins embedded in the substance of the body of the pancreas, located at right angles to each other

Discussion

Although a variety of foreign bodies have been retrieved from intra abdominal viscera, only one case of successful retrieval of intra-pancreatic foreign body has been reported till date.[1] In the above mentioned case, the metallic foreign body was found embedded in the body of the pancreas as a result of penetration from the level of D3. In our case, whether a similar path was the route adopted by the foreign body is a matter of conjecture. Unusual locations of metallic foreign bodies following silent perforation of the viscera include the liver and small bowel mesentery.[2] Intraoperative fluoroscopy and 'mapping' of the lesser sac and the pancreas with a non toothed forceps greatly aided in the localisation. Other techniques used for intraoperative localisation of metallic foreign bodies include electronic amplifier devices and magnetic probes.[3,4]

Conclusion

This case report highlights the unusual location of accidentally ingested metallic foreign bodies and the techniques useful in their retrieval. A good history regarding the occupation of a patient who presents with abdominal pain needs to be emphasised here. The patient was working as a technician for air conditioning systems and confessed to biting off pieces of metallic pins and wire, during his job, when retrospectively questioned regarding the same. He has been advised to be cautious while carrying on with his profession.

VIJAY RAMACHANDRAN[1]
BAILURU VISHWANATH TANTRY[2]
SONALI ULLAL[3]

Correspondence: Dr Vijay Ramachandran
Departments of Surgical Gastroenterology,[1] Gastroenterology[2] and Radiology[3]
KMC Hospital, Mangalore,
Karnataka – 575001, India
Email: drvijayr@gmail.com

References

1. Rasiqa I, Brebeanu G, Stãnescu S, Pascu A, Azamfirei I. Intrapancreatic foreign body. *Rev Chir Oncol Radiol O R L Oftalmol Stomatol Chir*. 1977;**26**:461–2.
2. Harjai MM, Gill M, Singh Y, Sharma A . Intra-abdominal needles: an enigma (a report of two cases). *Int Surg*. 2000;**85**:130–2.
3. Veselko M, Trobec R. Intraoperative localization of retained metallic fragments in missile wounds. *J Trauma*. 2000;**49**:1052–8.
4. Kandioler-Eckersberger D, Niederle B, Herbst F, Wenzl E. A magnetic probe to retrieve broken metallic parts of instruments during laparoscopic procedures. *Surg Endosc*. 2002;**16**:208–9.

Cytomegalovirus ileitis causing massive gastrointestinal haemorrhage in a patient following hepatic resection

Introduction

Cytomegalovirus (CMV) a common viral infection, affects 40-100% of adults, primarily in the first 2 decades of life.[1,2] It generally produces latent infection in the immunocompetent individuals; however it is known to produce clinical disease in patients who are immunocompromised like those with acquired immunodeficiency syndrome (AIDS), post-transplant recipients on immunosuppressive therapy, patients with malignancy or those on chemotherapeutic agents, on steroids, or elderly patients with impaired immune system.

CMV enteritis with lower gastrointestinal (GI) haemorrhage is a rare presentation. As CMV infection in immunocompromised patients can be lethal, it is important to diagnose and initiate early treatment. Though antiviral treatment is supposed to be curative, it is not always the case. Presented case illustrates an unusual presentation of CMV infection in the postoperative period, which posed a diagnostic dilemma and which despite antiviral drugs required surgical intervention.

Case Report

A 74 year old woman underwent an extended left hemihepatectomy for peripheral cholangiocarcinoma (3.5 × 3 × 2.5 cm) involving segments IVb and V of the liver. In the past, she had received radiotherapy for Hodgkin's disease at 29 years of age. Her past surgical history included a cholecystectomy, partial gastrectomy for benign ulcer disease, appendectomy and transurethral resection of early bladder cancer. Additional co-morbidities were hypothyroidism, stable angina, hypertension and atrial fibrillation.

The postoperative recovery was complicated by bile leak on the 3rd postoperative day (POD) leading to intra-abdominal sepsis and multi-organ failure. She was transferred to the intensive care unit (ICU) and required multi-organ support including mechanical ventilation, continuous veno-venous haemofiltration (CVVH) and inotropes. Intra-abdominal sepsis was controlled with percutaneous drainage and antibiotics. She made slow progress with the return of renal function and was weaned from inotropic support. On the 13th POD she developed diarrhoea which was empirically treated for *Clostridium difficile* infection. However, subsequent stool tests excluded this infection.

Diarrhoea continued and progressed to the passage of fresh blood clots per rectum. This was associated with hypotension and drop in haemoglobin from 10 gm to 6.3 gm%. Following resuscitation, an upper GI endoscopy failed to reveal the site of bleeding. Computed tomogram (CT) with angiography showed a thickened segment of distal ileum with evidence of extravasation of contrast into the lumen (**Figure 1**). Subsequent mesenteric angiography did not reveal any active site of bleeding. Continued bleeding and hemodynamic instability despite resuscitation prompted surgical resection of a portion of distal ileum which was found to be filled with blood at laparotomy. Gross examination of the resected small bowel noted a 12 cm long deep ulcerated lesion. Histology and immunostaining revealed cytomegalic cells with basophilic "Cowdry" intranuclear and intracytoplasmic inclusion bodies characteristic of cytomegalovirus (CMV) ileitis (**Figure 2**).