in an advanced stage when there is invasion of the hepatic parenchyma or lymphovascular invasion has already occurred leading to poor prognosis[2]. FDG PET has a limited role in NET as majority of them are metabolically inactive and do not take up 18- fluorodeoxyglucose (FDG). However avid uptake of 18-FDG has been seen in poorly differentiated NET which are aggressive in nature[6]. Similar finding was seen in our case.

HPE and IHC are of utmost importance for diagnosis. Currently available biomarkers are synaptophysin, chromogranin A and neuron-specific enolase (NSE)[2].

Treatment ranges from simple cholecystectomy to extensive radical resection. Platinum based chemotherapy with Etoposide has shown benefit[3]. Symptoms of carcinoid syndrome can be managed with somatostatin analogues[4]. Neoadjuvant protocols have not been established in view of rarity and there is no standardized established treatment modality.

Conclusion

GB-NET is a rare entity. Owing to its rarity, there is limited literature available. GB-NET should also be kept in differential diagnosis in a patient who has a Gall bladder mass. Currently there are no standard treatment protocols available. Early diagnosis and surgical intervention may give the patient a better outcome.

Highlights

- GB-NET is an extremely rare disease accounting for approximately 0.2% of all NETs
- Large tumor size without evidence of systemic metastases
- The patient was well preserved despite having such a large tumor
- The lesion was deemed resectable on staging laparoscopy

References

1. Modlin IM, Lye KD, Kidd M. A 5-decade analysis of 13,715 carcinoid tumors. Cancer. 2003 Feb 15;97(4):934–59.
2. Kumar K, Tariq H, Ahmed R, Chukwunonso C, Niazi M, Ihimoyan A. Small-Cell Type, Poorly Differentiated Neuroendocrine Carcinoma of the Gallbladder: A Case Report and Review of the Literature. Case Rep Oncol Med. 2019 Apr 1;2019:e8968034.
3. Yao JC, Hassan M, Phan A, Dagohoy C, Leary C, Mares JE, et al. One hundred years after "carcinoid": epidemiology of and prognostic factors for neuroendocrine tumors in 35,825 cases in the United States. J Clin Oncol. 2008 Jun 20;26(18):3063–72.
4. Marak JR, Kumar T, Dwivedi S, Khurana R. Neuroendocrine tumor of the gall bladder: A rare case report with review of literature. Radiol Case Rep. 2023 Aug 26;18(11):3912–6.
5. Shimizu T, Tajiri T, Akimaru K, Arima Y, Yoshida H, Yokomuro S, et al. Combined neuroendocrine cell carcinoma and adenocarcinoma of the gallbladder: report of a case. J Nippon Med Sch Nippon Ika Daigaku Zasshi. 2006 Apr;73(2):101–5.
6. Maxwell JE, Howe JR. Imaging in neuroendocrine tumors: an update for the clinician. Int J Endocr Oncol. 2015;2(2):159–68.
7. Yun SP, Shin N, Seo HI. Clinical outcomes of small cell neuroendocrine carcinoma and adenocarcinoma of the gallbladder. World J Gastroenterol. 2015 Jan 7;21(1):269-75.

Rare Case of Spontaneous Lumbar Hernia

Sangeetha Siva[1], Sathish N[2], Sunil Kumar Alur[3]

[1]Department of General Surgery, St Philomena's Hospital, Bangalore, Karnataka, India. [2]Department of General Surgery, Manipal Hospital, Yeshwanthpur, Bangalore, Karnataka, India. [3]Trustwell Hospital, Bangalore, Karnataka, India.

Corresponding Author: *Dr Sangeetha Siva*
Email: sangeethasivas@gmail.com

Lumbar hernias are rare hernias. Hafner et al[1] stated that a general surgeon will get only one opportunity to repair a lumbar hernia during his life time. Lumbar hernia was first reported by P. Barbette in 1672. Since then, only about 300 cases have been reported[2].

The lumbar region is bounded superiorly by the 12th rib, inferiorly by the iliac crest, medially by

the erector spinae muscles and laterally by the external oblique muscle. Lumbar hernias occur through superior and inferior lumbar triangles in the lumbar region. Inferior lumbar triangle is bounded by the iliac crest inferiorly, external oblique muscle laterally, latismus dorsi muscle medially. Superior lumbar triangle which is the larger one, is an inverted triangle, the base is formed by 12th rib and the lower edge of the serrratus posterior inferior muscle, anterior boundary is formed by the internal oblique muscle and the roof is formed by external oblique and latissimus dorsi[2].

Lumbar hernias can be congenital (20%) or acquired (80%). An acquired hernia may be primary or secondary. Secondary hernias can be spontanoues or secondary to trauma, surgery and infection. Several risk factors have been described for spontaneous hernias, including age, obesity, extreme thinness, intense wasting, chronic debilitating disease, muscular atrophy, chronic bronchitis, infected wound, and postoperative sepsis[3].

Figure 1: Globular swelling in left lumbar region, lumbar hernia.

Elective surgery remains the mainstay of treatment. Despite the different techniques recommended, the open approach is most affordable in our setup. We report a case of primary spontaneous lumbar hernia which was repaired by an open approach.

Case Report

50 year old female patient came with complaints of swelling and discomfort in left lumbar region for few weeks. She had no bowel or bladder disturbances. There was no history of previous surgery or trauma. On examination there was a globular, soft, non-tender, reducible, non-pulsatile swelling of size 6×6 cm located in the left lumbar region with an expansile cough impulse (**Figure 1**). The swelling was more prominent with straining and disappeared with prone position. Examination of rest of the abdomen, right flank, back & other hernial orifices was normal.

CT revealed evidence of a focal defect on posterior abdominal wall in the left paravertebral tranversalis fascia at L2 vertebral level, measuring 10×9 mm, with thinning of left latismus dorsi muscle and herniation of omental fat. Sac measured 65×32×34 mm (**Figure 2**).

Patient was taken up for surgery after routine pre operative investigations. Under spinal anesthesia, the

Figure 2: CT sagittal and axial view showing left lumbar Hernia.

patient was placed in right lateral position. Longitudinal incision was placed over the lumbar region. The hernia sac was identified and opened. The content being the extra peritoneal fat, was completely reduced (**Figure 3**). The size of the defect was about 1×1 cm which was primarily repaired with (1-0) polypropylene interrupted suture and then an onlay polypropylene mesh was placed over the defect (**Figure 4**). Overlying muscle was closed using polypropylene continuous sutures. The skin was closed with staplers. The postoperative period was uneventful and the patient was discharged on 1st postoperative day.

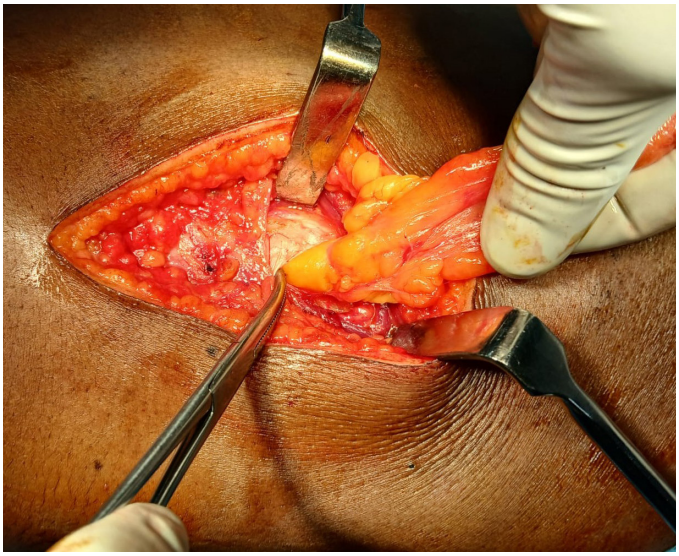

Figure 3: Per operative image showing defect with contents.

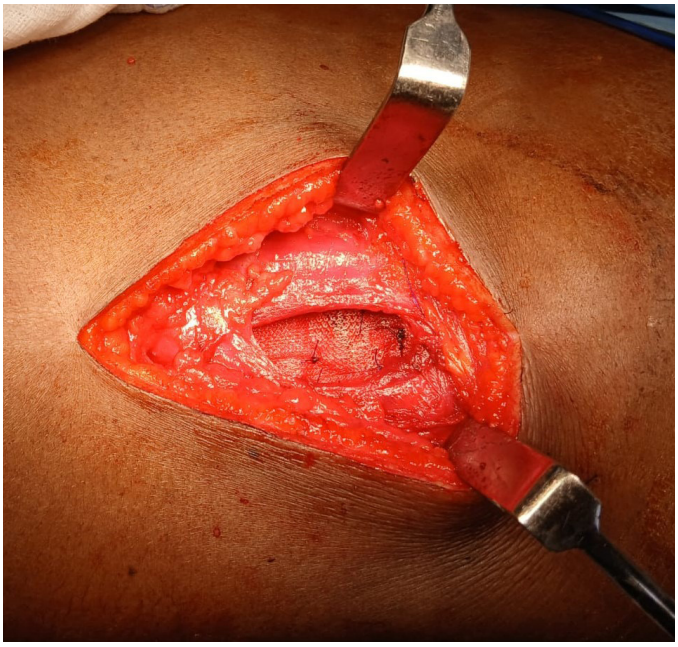

Figure 4: Per operative image showing defect closed with prolene mesh.

Discussion

Lumbar hernias present as a swelling on one or both sides over the back which increases in size on coughing and reduces on lying down. Patients may present with discomfort or nonspecific abdominal pain or back pain. Complications are rare but may occur in the form of bowel obstruction and sometimes hydronephrosis. The most common differential diagnosis is lipoma.

USG may not be helpful in diagnosis and CT scan remains the gold standard for detection of lumbar hernia and also for planning the surgical treatment.

91% of the patients present as non emergency cases and only 9% present as surgical emergencies to the hospitals[4]. Surgical treatment is the only option and it should be considered early to avoid complications.

Conclusion

Lumbar hernias are rare. USG may not be helpful in diagnosis of lumbar hernia, CT scan is the investigation of choice. Laparoscopy / open repair are the options for lumbar hernia mesh repair. Elective repair is recommended to avoid complication due to hernia.

References

1. Hafner C., Wylie J., Jr., Brush B.E. Petit's lumbar hernia: repair with Marlex mesh. Arch Surg. 1963;86:180–186.
2. Moreno-Egea A., Baena E.G., Calle M.C., Martínez J.A., Albasini J.L. Controversies in the current management of lumbar hernias. Arch Surg. 2007;1:82–88.
3. Rajasekar M, Kumar KV. A rare case of lumbar hernia: a case report with review of literature, IOSR, 2015; 14(3): 10–13
4. Alfredo M.-E., Enrique G.B., Miquel C.C., José Antonio T.M., José L.A. Controversies in the current management of lumbar hernias. Arch Surg. 2007;142:82–88.