Internal hernias account for 0.5% of all cases of intestinal obstruction.[5] Paraduodenal hernia is the most common type, accounting for 53% of cases.[5-8] Paraduodenal hernia can present at any age but is typically seen between the fourth and sixth decades of life.[9] It is more common in men than women, with a ratio of 3:1,[8] and is more frequent on the left than right, with a ratio of 3: 1.[1] Fifty per cent of paraduodenal hernias cause obstruction, the remainder are diagnosed incidentally at exploratory laparotomy or at necropsy.[8,9]

The mortality of obstructed internal hernia exceeds 50%,[6,8] reflecting the large proportion of patients who present with intestinal obstruction and ischaemia requiring emergency surgery.[6,10,11] Consequently, all paraduodenal hernias, even those diagnosed incidentally, should be repaired.[1,6,11]

MUNEER AHMAD ZAZ
USVA KAWOOSA
ARJMAND REYAZ
IRFAN JAN

Correspondence: Dr. Muneer Ahmad Zaz
Department of Surgery, SKIMS Medical College Hospital, Bemina, Srinagar, Jammu & Kashmir, India - 190010
Email: munnzah@yahoo.com

References

1. Bartlett MK, Wang C, Williams WH. The surgical management of paraduodenal hernia. *Ann Surg*. 1968;**168**:249–54.
2. Tireli M. Left paraduodenal hernia. *Br J Surg*. 1982;**69**:114.
3. Filtzer H, Sedgwick CE. Strangulated paraduodenal hernia. Report of a case. *Surg Clin North Am*. 1973;**53**:371–4.
4. Willwerth BM, Zollinger RM, Jr., Izant RJ, Jr. Congenital mesocolic (paraduodenal) hernia. Embryologic basis of repair. *Am J Surg*. 1974;**128**:358–61.
5. Lee TK, Voon FC, Chow KW, Teo NH. Unusual variant of right paraduodenal hernia. *Aust N Z J Surg*. 1990;**60**:483–5.
6. Freund H, Berlatzky Y. Small paraduodenal hernias. *Arch Surg*. 1977;**112**:1180–3.
7. Ghahremani GG. Internal abdominal hernias. *Surg Clin North Am*. 1984;**64**:393–406.
8. Newsom BD, Kukora JS. Congenital and acquired internal hernias: unusual causes of small bowel obstruction. *Am J Surg*. 1986;**152**:279–85.
9. Brigham RA, Fallon WF, Saunders JR, Harmon JW, d'Avis JC. Paraduodenal hernia: diagnosis and surgical management. *Surgery*. 1984;**96**:498–502.
10. Turley K. Right paraduodenal hernia: a source of chronic abdominal pain in the adult. *Arch Surg*. 1979;**114**:1072–4.
11. Dengler WC, Reddy PP. Right paraduodenal hernia in childhood: a case report. *J Pediatr Surg*. 1989;**24**:1153–4.

Mucinous cystadenoma of the pancreas associated with recurrent pancreatitis

We report the unusual occurrence of a patient with recurrent pancreatitis caused by the underlying presence of a benign mucinous cystadenoma of the distal pancreas. There are only two previous case reports of a mucinous cystadenoma causing acute pancreatitis[1,2] and two case reports of the coexistence of a pancreatic pseudocyst with a mucinous cystadenoma.[3,4]

Case Report

A 54-year old female was admitted for recurrent bouts of central abdominal pain radiating to back since last 6 months. Her past medical history was significant for hypertension, which was currently controlled. The admission laboratory tests showed normal liver function tests, normal white blood cell count, but her amylase and lipase were 216 U/L (normal range, 27-137 U/L) and 2217 U/L (normal range, <190 U/L), respectively. She was treated for acute pancreatitis and was discharged 7 days later.

However, she returned six weeks after discharge with recurrent mid-epigastric pain with radiation to her back, nausea, and vomiting, and continued early satiety. Her laboratory tests again showed elevated amylase and lipase of 498U/L and 3025 U/L, respectively. Contrasted abdominal CT showed a 10 cm cystic mass in the midbody/tail of the pancreas with an anterior rim of normal appearing pancreas (**Figure 1**).

Endoscopic retrograde cholangiopancreatography (ERCP) revealed a normal caliber pancreatic duct with an abrupt cutoff at the distal duct. She underwent exploratory laparotomy. After gaining access to the lesser sac, a 10 cm cystic lesion was identified at the junction of the body and tail of the pancreas (**Figure 2**).

However, there were dense adhesions and inflammation surrounding the 10 cm cystic lesion at the junction of body and the tail of the pancreas. *Enbloc* distal pancreas and spleen was removed (**Figure 3**). The final pathology confirmed the presence of a mucinous cystadenoma with its characteristic features: a mucin-producing columnar epithelium lining the cyst wall, underlying ovarian-type stromal tissue, and no evidence of dysplasia. The patient had an uneventful recovery, began to tolerate oral intake, and was discharged 7 days after surgery.

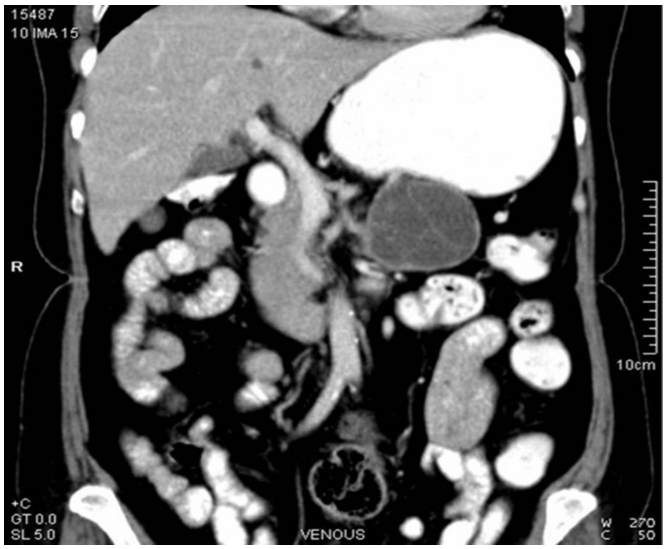

Figure 1: CT scan of the abdomen showing a 10 cm cystic mass in the body/tail of the pancreas.

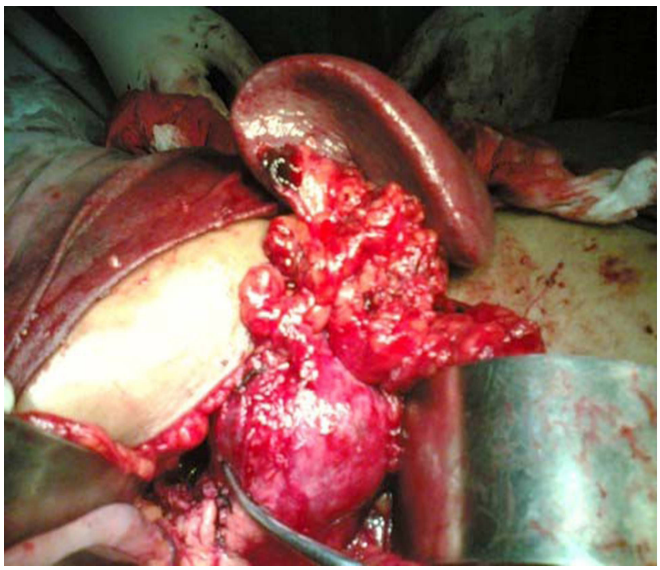

Figure 2: Intraoperative cystic lesion of pancreas with dense adhesions.

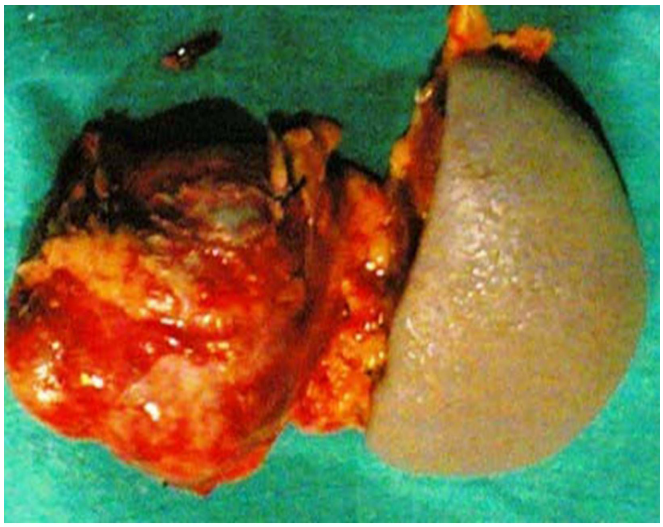

Figure 3: Specimen of distal pancreatectomy with splenectomy.

Discussion

Mucinous cystadenomas are a benign type of mucinous cystic neoplasm of the pancreas (MCNs). Patients with mucinous cystadenomas have a mean presentation of 48 years with a distinct female predominance as high as 9:1 in some series.[5-6] These cystic tumors are typically large (50% are greater than 5 cm) and most (greater than 50%) are located in the distal body and tail of the pancreas. Patients most often present with nonspecific abdominal pain, nausea, vomiting, and weight loss.

In published series there are only two cases in the literature that attribute the development of acute pancreatitis to a mucinous cystadenoma.[1,2] Likewise, there are only two cases that describe the coexistence of a pseudocyst and a mucinous cystadenoma.[3-4] There are no reported cases of a mucinous cystadenoma causing recurrent pancreatitis. Rattner et al. found that in computed tomography neoplastic process is highly suggestive by presence of solid components in the wall of the cyst.[7] Most pseudocysts are single and have few solid components, septae or loculations, or calcifications in the cyst wall. Hsieh and colleagues reported that, magnetic resonance imaging easily differentiated a pseudocyst from a mucinous cystadenoma.[4] T1-weighted, T2-weighted, and gadolinium-enhanced images may delineate loculations, septae, and further define the surrounding tissue in order to differentiate the cystic lesions.

Endoscopic ultrasound is a diagnostic tool which provides morphologic detail, and sampling of fluid from the lesion for measurement of enzymes, viscosity, measurement of tumor markers, and cytologic examination. Song et al. observed that pseudocysts contained echogenic debris and demonstrated parenchymal changes more often than cystic neoplasm. In addition, internal septae were seen with EUS more frequently in cystic neoplasms.[8]

Cyst fluid may be used for diagnosis by cytology and measurement of various tumor markers. A high concentration of amylase in the cyst fluid is diagnostic of a pancreatic psuedocyst.[9] Similarly, a high carcinoembryonic antigen (CEA) is indicative of a mucinous cystadenoma and a CEA of greater than 400 is potentially predictive of malignancy.[10] Mucin and mucinous cells are characteristic of mucinous cystic neoplasm, glycogen-staining cells are seen in serous cystadenomas, and inflammatory cells and histiocytes are associated with pseudocysts. Even pancreatic acinar cell carcinoma may

present with features of pancreatitis.[11] Fine needle aspiration cytology provides tissue diagnosis in such cases.

Cystic pancreatic tumors constitute for about 10-15% of pancreatic cysts and less than 1% of pancreatic neoplasms.[12] World Health Organization (WHO) classified cystic pancreatic neoplasms into three main categories, mucinous variety (45%), serous variety (16%), and intraductal papillary mucinous neoplasm (IPMNs) (32%).[13] Sahani DV et al. have suggested a classification scheme for pancreatic cysts that is based on the imaging morphologic features of the cyst into four subtypes: (a) unilocular cysts, (b) microcystic lesions, (c) macrocystic lesions and (d) cysts with a solid component. Multiple unilocular cysts are most often pseudocysts resulting from prior pancreatitis.[14] Other causes of multiple cysts include von Hippel–Lindau disease and rarely IPMN. In von Hippel–Lindau disease, the pancreas is otherwise healthy and cysts may also be present in the kidneys or liver.[15] The presence of ovarian-type stroma has now becoming an essential requirement for the diagnosis of MCN, and when defined as such, MCN is seen almost exclusively in women of perimenopausal age group as thick-walled multilocular cystic mass in the tail of the pancreas.[16]

Benign and malignant cystic neoplasms are simply differentiated based on pathology. Any cystic neoplasm exhibiting invasive components is considered a malignant cystadenocarcinoma. For patients with benign serous or mucinous cystadenomas, complete resection is curative. Patients with resected mucinous cystadenocarcinomas typically live much longer than those with resected ductal adenocarcinoma, with an approximate 50 percent 5-year survival.[17]

DHARMDAS PARAMHANS
SAPNA SHUKLA
RAJ KUMAR MATHUR

Correspondence: Dr. Dharmdas Paramhans
Department of surgery,
M.Y.H Hospital and M.G.M Medical College
Indore, Madhya Pradesh, India-452001
Email: dparamhans@gmail.com

References

1. Sperti C, Pasquali C, Davoli C, Polverosi R, Pedrazzoli S. Mucinous cystadenoma of the pancreas as a cause of acute pancreatitis. *Hepatogastroenterology*. 1998;**45**:2421–4.
2. Fischer CP, Pope I, Garden OJ. Mucinous cystic tumour of the pancreas presenting with acute pancreatitis. *HPB (Oxford)*. 2001;**3**:271–3.
3. Russell RT, Sharp KW. Mucinous cystadenoma of the pancreas associated with acute pancreatitis and concurrent pancreatic pseudocyst. *Am Surg*. 2005;**71**:292–7.
4. Hsieh CH, Tseng JH, Huang SF. Co-existence of a huge pseudocyst and mucinous cystadenoma: report of a case and the value of magnetic resonance imaging for differential diagnosis. *Eur J Gastroenterol Hepatol*. 2002;**14**:191–4.
5. Sarr MG, Carpenter HA, Prabhakar LP, Orchard TF, Hughes S, van Heerden JA, et al. Clinical and pathologic correlation of 84 mucinous cystic neoplasms of the pancreas: can one reliably differentiate benign from malignant (or premalignant) neoplasms? *Ann Surg*. 2000;**231**:205–12.
6. Fernandez-del Castillo C, Targarona J, Thayer SP, Rattner DW, Brugge WR, Warshaw AL. Incidental pancreatic cysts: clinicopathologic characteristics and comparison with symptomatic patients. *Arch Surg*. 2003;**138**:427–3; discussion 33–4..
7. Rattner DW, Fernandez-del Castillo C, Warshaw AL. Cystic pancreatic neoplasms. *Ann Oncol*. 1999;**10 Suppl 4**:104–6.
8. Song MH, Lee SS, Park JS, Seo DW, Lee SK, Kim MH, et al. The role of endoscopic ultrasonography in pancreatic cystic lesions [abstract]. *Gastrointest Endosc*. 2002;**55**:AB249.
9. Brugge WR. Diagnosis and management of relapsing pancreatitis associated with cystic neoplasms of the pancreas. *World J Gastroenterol*. 2008;**14**:1038–43.
10. Van Dam J. EUS in cystic lesions of the pancreas. *Gastrointest Endosc*. 2002;**56**:S91–3.
11. Thomas PC, Nash GF, Aldridge MC. Pancreatic acinar cell carcinoma presenting as acute pancreatitis. *HPB (Oxford)*. 2003;**5**:111–3.
12. Fernandez-del Castillo C, Warshaw AL. Cystic neoplasms of the pancreas. *Pancreatology*. 2001;**1**:641–7.
13. Kloppel G, Luttges J. WHO-classification 2000: exocrine pancreatic tumors. *Verh Dtsch Ges Pathol*. 2001;**85**:219–28.
14. Sahani DV, Kadavigere R, Saokar A, Fernandez-del Castillo C, Brugge WR, Hahn PF. Cystic pancreatic lesions: a simple imaging-based classification system for guiding management. *Radiographics*. 2005;**25**:1471–84.
15. Friedrich CA. Von Hippel-Lindau syndrome. A pleomorphic condition. *Cancer*. 1999;**86**:2478–82.
16. Murakami Y, Uemura K, Ohge H, Hayashidani Y, Sudo T, Sueda T. Intraductal papillary-mucinous neoplasms and mucinous cystic neoplasms of the pancreas differentiated by ovarian-type stroma. *Surgery*. 2006;**140**:448–53.
17. Wilentz RE, Albores-Saavedra J, Zahurak M, Talamini MA, Yeo CJ, Cameron JL, et al. Pathologic examination accurately predicts prognosis in mucinous cystic neoplasms of the pancreas. *Am J Surg Pathol*. 1999;**23**:1320–7.