## References


1. Rooney TB, Schofer JM, Stanley MD, Banks SL. Biliary cystadenoma of the gallbladder. *AJR Am J Roentgenol*. 2005;**185**:1571–2.
2. Florman SS, Slakey DP. Giant biliary cystadenoma: case report and literature review. *Am Surg*. 2001;**67**:727–32.
3. Wang YJ, Lee SD, Lai KH, Wang SS, Lo KJ. Primary biliary cystic tumors of the liver. *Am J Gastroenterol*. 1993;**88**:599–603.
4. Kokubo T, Itai Y, Ohtomo K, Itoh K, Kawauchi N, Minami M. Mucin-hypersecreting intrahepatic biliary neoplasms. *Radiology*. 1988;**168**:609–14.
5. Marcial MA, Hauser SC, Cibas ES, Braver J. Intrahepatic biliary cystadenoma. Clinical, radiological, and pathological findings. *Dig Dis Sci*. 1986;**31**:884–8.
6. Okamura T, Murakami S, Nishioka Y, Hirayama R, Mishima Y, Awazu R. Biliary cystadenoma of the extrahepatic bile ducts: report of a case and review of the literature. *Jpn J Surg*. 1987;**17**:281–8.
7. Preetha M, Chung AY, Lim-Tan SK, Lim DT, Thng CH. Intrahepatic biliary cystadenoma presenting with obstructive jaundice. *Asian J Surg*. 2004;**27**:243–5.
8. Catinis GE, Frey DJ, Skinner JW, Balart LA. Hepatic cystadenoma: an unusual presentation. *Am J Gastroenterol*. 1998;**93**:827–9.
9. Sutton CD, White SA, Berry DP, Dennison AR. Intrahepatic biliary cystadenoma causing luminal common bile duct obstruction. *Dig Surg*. 2000;**17**:297–9.
10. Choi BI, Lim JH, Han MC, Lee DH, Kim SH, Kim YI, et al. Biliary cystadenoma and cystadenocarcinoma: CT and sonographic findings. *Radiology*. 1989;**171**:57–61.
11. Palacios E, Shannon M, Solomon C, Guzman M. Biliary cystadenoma: ultrasound, CT, and MRI. Gastrointest *Radiol*. 1990;**15**:313–6.
12. Korobkin M, Stephens DH, Lee JK, Stanley RJ, Fishman EK, Francis IR, et al. Biliary cystadenoma and cystadenocarcinoma: CT and sonographic findings. *AJR Am J Roentgenol*. 1989;**153**:507–11.
13. Federle MP, Filly RA, Moss AA. Cystic hepatic neoplasms: complementary roles of CT and sonography. *AJR Am J Roentgenol*. 1981;**136**:345–8.
14. Thomas KT, Welch D, Trueblood A, Sulur P, Wise P, Gorden DL, et al. Effective treatment of biliary cystadenoma. *Ann Surg*. 2005;**241**:769–73; discussion 73–5.


# Paraduodenal hernia: case report of a rare internal hernia presenting as acute abdomen

## Introduction

Paraduodenal hernia is a rare congenital internal hernia which arises from an error of rotation of the midgut with entrapment of the small intestine beneath the developing colon. It is important as it usually presents as intestinal obstruction, and before laparotomy is often misdiagnosed. Mortality increases significantly with delays in surgical treatment.

Paraduodenal hernia, also referred to as internal, congenital, retroperitoneal, or meso-colonic hernia, is a herniation resulting from anomalies of rotation and reduction of the midgut loop in the embryo. This hernia occurs when the small intestine becomes trapped beneath the colon because of anomalous rotation of the mesentery of the developing colon. The duodenum and small intestine become trapped in a sac lined by peritoneum, behind the mesentery of the colon, either to the left or to the right of the midline.[1]

## Case report

A 60 year old man, hailing from Nowgam village, was admitted in the emergency department with a history of severe abdominal pain of 8 hours duration. Pain was sudden in onset, colicky and more severe in the right upper abdomen to begin with. Subsequently the pain became constant and generalized. He had vomited once and passed no flatus. He had been keeping well except a few episodes of upper abdominal colic in recent years, which had resolved spontaneously. There was no significant past surgical history.

On examination the patient appeared to be in distress and was dehydrated with a pulse rate of 96 beats/min. He was afebrile and his blood pressure was normal. Abdominal examination revealed fullness in right upper quadrant with a palpable tender lump of approximately 9 × 6 cm size. There was overlying muscle guarding and bowel sounds were sluggish.

White cell count was 13,000/mm$^3$ with 82% neutrophils. Electrolytes were normal and amylase was not raised. Abdominal X-rays (**Figure 1**) showed slightly distended gut loops in right upper abdomen with no free gas under the diaphragm. Ultrasonography (USG) revealed a gut mass in right upper quadrant and free fluid in Morrison's pouch.

A provisional diagnosis of acute intestinal obstruction due to a primary or, more likely, a secondary intussusception was made and after initial resuscitation, laparotomy was planned.

Laparotomy showed small bowel obstruction because of a right paraduodenal hernia at the duodenal-jejunal flexure. The palpable lump, and the gut mass visualised on USG was actually

Figure 1: Erect X-ray abdomen showing distended gut loops in upper abdomen with a few air-fluid levels.

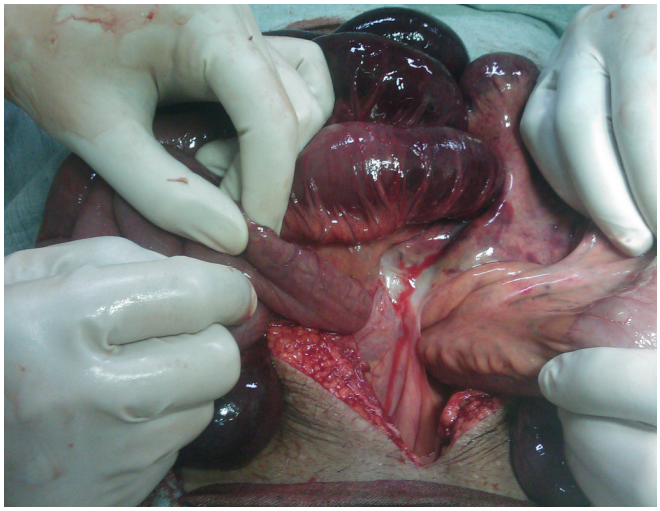

Figure 2: Trapped jejunum being delivered from the sac after widening of neck.

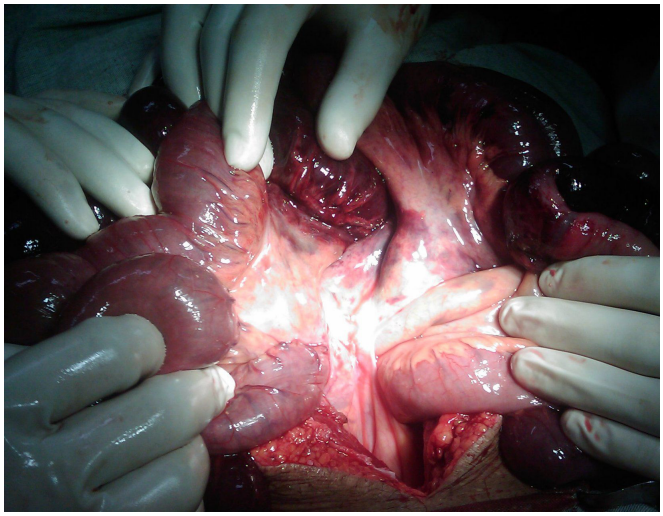

Figure 3: Narrow neck had caused gangrene of the trapped bowel.

the small gut entrapped in the hernia and not the intussusception, as presumed initially. The sac was inferolateral to the third (transverse) part of duodenum and extended behind the ascending mesocolon and right half of transverse mesocolon. The superior mesenteric artery and the right colic vein were in the free edge of the hernia. The small bowel was reduced from the hernial sac after widening the neck. Due to the tight neck the bowel trapped in the hernia was strangulated and had patchy gangrenous areas. About 30% of proximal small bowel had to be resected, and an end to end hand sewn anastomosis fashioned. The neck of the sac was obliterated by suturing the posterior peritoneum (**Figures 2,3**).

The patient showed rapid improvement post operatively and was discharged on 7th post operative day, after he had tolerated soft orals and moved bowels.

## Discussion

This case illustrates the typical onset of bowel obstruction caused by paraduodenal hernia, with rapidly progressing acute abdominal pain from ischaemic bowel. As it is a closed loop obstruction, damage to the bowel occurs early, accounting for the high mortality rate in this condition. Presentation is dramatic, often with hypovolaemic shock and peritonism.

Paraduodenal hernia can be divided into two types: left and right. A left sided hernia is produced by malrotation of the umbilical loop. As the small intestine is reduced into the abdominal cavity, it is caught beneath the mesentery of the descending colon. The caecum is completely rotated and lies in the normal position in the right iliac fossa. The sac points downward and to the left towards the descending colon. The free edge of the sac contains the inferior mesenteric artery and vein and the left colic artery, and their branches are integral part of the hernia sac. The anterior wall of the sac is made up of the mesocolon of descending colon.[1-4]

A right paraduodenal hernia is produced when the umbilical loop fails to rotate completely and is caught beneath the caecum. The small intestine becomes imprisoned behind its mesentery. The major portion of the small intestine remains to the right of the superior mesenteric artery. The anterior wall of sac is made up of the mesentery of the ascending colon and transverse colon. Right sided paraduodenal hernias contain the superior mesenteric artery and iliocolic artery in the free edge of the sac. The hernial orifice is to the right of midline and the peritoneal sac directed downward and to the right.[1-4]

Internal hernias account for 0.5% of all cases of intestinal obstruction.[5] Paraduodenal hernia is the most common type, accounting for 53% of cases.[5-8] Paraduodenal hernia can present at any age but is typically seen between the fourth and sixth decades of life.[9] It is more common in men than women, with a ratio of 3:1,[8] and is more frequent on the left than right, with a ratio of 3: 1.[1] Fifty per cent of paraduodenal hernias cause obstruction, the remainder are diagnosed incidentally at exploratory laparotomy or at necropsy.[8,9]

The mortality of obstructed internal hernia exceeds 50%,[6,8] reflecting the large proportion of patients who present with intestinal obstruction and ischaemia requiring emergency surgery.[6,10,11] Consequently, all paraduodenal hernias, even those diagnosed incidentally, should be repaired.[1,6,11]

MUNEER AHMAD ZAZ
USVA KAWOOSA
ARJMAND REYAZ
IRFAN JAN

*Correspondence: Dr. Muneer Ahmad Zaz*
*Department of Surgery, SKIMS Medical College Hospital, Bemina, Srinagar, Jammu & Kashmir, India - 190010*
*Email: munnzah@yahoo.com*

## References

1. Bartlett MK, Wang C, Williams WH. The surgical management of paraduodenal hernia. *Ann Surg*. 1968;**168**:249–54.
2. Tireli M. Left paraduodenal hernia. *Br J Surg*. 1982;**69**:114.
3. Filtzer H, Sedgwick CE. Strangulated paraduodenal hernia. Report of a case. *Surg Clin North Am*. 1973;**53**:371–4.
4. Willwerth BM, Zollinger RM, Jr., Izant RJ, Jr. Congenital mesocolic (paraduodenal) hernia. Embryologic basis of repair. *Am J Surg*. 1974;**128**:358–61.
5. Lee TK, Voon FC, Chow KW, Teo NH. Unusual variant of right paraduodenal hernia. *Aust N Z J Surg*. 1990;**60**:483–5.
6. Freund H, Berlatzky Y. Small paraduodenal hernias. *Arch Surg*. 1977;**112**:1180–3.
7. Ghahremani GG. Internal abdominal hernias. *Surg Clin North Am*. 1984;**64**:393–406.
8. Newsom BD, Kukora JS. Congenital and acquired internal hernias: unusual causes of small bowel obstruction. *Am J Surg*. 1986;**152**:279–85.
9. Brigham RA, Fallon WF, Saunders JR, Harmon JW, d'Avis JC. Paraduodenal hernia: diagnosis and surgical management. *Surgery*. 1984;**96**:498–502.
10. Turley K. Right paraduodenal hernia: a source of chronic abdominal pain in the adult. *Arch Surg*. 1979;**114**:1072–4.
11. Dengler WC, Reddy PP. Right paraduodenal hernia in childhood: a case report. *J Pediatr Surg*. 1989;**24**:1153–4.

# Mucinous cystadenoma of the pancreas associated with recurrent pancreatitis

We report the unusual occurrence of a patient with recurrent pancreatitis caused by the underlying presence of a benign mucinous cystadenoma of the distal pancreas. There are only two previous case reports of a mucinous cystadenoma causing acute pancreatitis[1,2] and two case reports of the coexistence of a pancreatic pseudocyst with a mucinous cystadenoma.[3,4]

## Case Report

A 54-year old female was admitted for recurrent bouts of central abdominal pain radiating to back since last 6 months. Her past medical history was significant for hypertension, which was currently controlled. The admission laboratory tests showed normal liver function tests, normal white blood cell count, but her amylase and lipase were 216 U/L (normal range, 27-137 U/L) and 2217 U/L (normal range, <190 U/L), respectively. She was treated for acute pancreatitis and was discharged 7 days later.

However, she returned six weeks after discharge with recurrent mid-epigastric pain with radiation to her back, nausea, and vomiting, and continued early satiety. Her laboratory tests again showed elevated amylase and lipase of 498U/L and 3025 U/L, respectively. Contrasted abdominal CT showed a 10 cm cystic mass in the midbody/tail of the pancreas with an anterior rim of normal appearing pancreas (**Figure 1**).

Endoscopic retrograde cholangiopancreatography (ERCP) revealed a normal caliber pancreatic duct with an abrupt cutoff at the distal duct. She underwent exploratory laparotomy. After gaining access to the lesser sac, a 10 cm cystic lesion was identified at the junction of the body and tail of the pancreas (**Figure 2**).

However, there were dense adhesions and inflammation surrounding the 10 cm cystic lesion at the junction of body and the tail of the pancreas. *Enbloc* distal pancreas and spleen was removed (**Figure 3**). The final pathology confirmed the presence of a mucinous cystadenoma with its characteristic features: a mucin-producing columnar epithelium lining the cyst wall, underlying ovarian-type stromal tissue, and no evidence of dysplasia. The patient had an uneventful recovery, began to tolerate oral intake, and was discharged 7 days after surgery.