Discussion

Schawanoma are the variant of gastrointestinal stromal tumors (GIST) like leiomyoma, leiomyoblastoma, and leiomyosarcoma. They are differentiated from other GIST by immunohistochemistry. Such tumors are strongly positive for S-100 protein and negative for CD34, smooth-muscle actin, and desmin.[1,2] There is limited data regarding incidence, presentation and outcome of these tumors. In one study, they have almost the same incidence in men and women and the median age of presentation was 65 years.[3] Schwannomas appear more frequently in the stomach and the small intestine, while presentation in the colon or rectum is uncommon.[4,5] Among the colonic schwannomas, most common location was reported in caecum followed by sigmoid and rectosigmoid regions, transverse colon, descending colon and rectum.[6,7] They can present with obstruction or bleed. Intussusception is rare in adults. Endoscopic biopsy of the mass is most of the time non-contributory and these tumors are diagnosed on postoperative specimen. Endoscopic ultrasound guided fine needle aspiration can be used as a diagnostic tool. Most of the schwannomas of the colon so far described are benign with few exceptions which showed malignant potential. Radical excision with wide free margins is mandatory and is curative; however, these tumors can have local recurrence and malignant transformation.

HAMID ULLAH WANI[1]
AHMED AL OMAIR[1]
WAFA AL SHAKWEER[2]
BILAL AHMED[3]

Correspondence: Dr. Hamid ullah Wani
Division of Gastroenterology, Department of Medicine[1]
Department of Pathology[2]
King Fahad Medical City, Riyadh, 11525, Saudi Arabia.
Max Healthcare, New Delhi, India[3]
Email: drhamidwani@gmail.com

References

1. Miettinen M, Shekitka KM, Sobin LH. Schwannomas in the colon and rectum. A clinicopathologic and immunohistochemical study of 20 cases. *Am J Surg Pathol*. 2001;**25**:846–55.
2. Miettinen M, Virolainen M, Sarlomo-Rikala M. Gastrointestinal stromal tumors-value of CD34 antigen in their identification and separation from true leiomyomas and schwannomas. *Am J Surg Pathol*. 1995;**19**:207–16.
3. Sivak MV Jr, Sullivan BH Jr, Farmer RG. Neurogenic tumors of the small intestine. Review of the literature and report of a case with endoscopic removal. *Gastroenterology*. 1975;**68**:374–80.
4. Fotiadis CI, Kouerinis IA, Papandreou I, Zografos GC, Agapitos G. *World J Gastroenterol*. 2005;**11**:5079–81.
5. Hirasaki S, Kanzaki H, Fujita K, Suzuki S, Kobayashi K, Suzuki H, et al. *World J Gastroenterol.* 2008;**14**:638–40.
6. Bhardwaj K, Bal MS, Kumar P. Rectal schwannoma. *Indian J Gastroenterol*. 2002;**21**:116–7.
7. Tomozawa S, Masaki T, Matsuda K, Yokoyama T, Ishida T, Muto T. *World J Gastroenterol.* 1998;**33**:872–5.

Acute idiopathic gastric gangrene with perforation

Introduction

Acute dilatation of stomach leading to perforation and gangrene is a very rare condition. First described in 1833 by S E Duplay,[1] acute gastric dilatation has been documented in a range of conditions of which the gastric volvulus is the commonest. The clinical presentation tends to be as acute abdomen with features of abdominal pain accompanied by copious vomiting in greater than 90% of cases. Abdominal distension is a pathognomonic sign of acute gastric dilatation.[2]

Case Report

A 64 year old male presented with upper abdominal pain of 4 days duration, initially colicky later continuous and generalized. He had persistent vomiting and obstipation of 2 days duration. There was no history of fever, trauma, haematemesis / melaena or similar episodes in the past. There were no known co-morbidities.

On examination he bore an anxious look and was afebrile with tachycardia. He was tachypnoeic, hypotensive with pallor and dehydration. Abdomen was grossly distended and tender with guarding and rigidity. Bowel sounds were absent and

there was no free fluid. Rectal examination revealed a boggy swelling anteriorly. Systemic examination was not contributory.

Lab parameters revealed a leukocytosis of 13,200/cu. mm. Other metabolic and biochemical parameters were within normal limits. Plain X-ray abdomen revealed a grossly dilated stomach with free air under the diaphragm.

A clinical diagnosis of a hollow viscous perforation was made and an emergency exploratory laparotomy carried out. Operative findings revealed a grossly dilated stomach with gangrenous proximal stomach. There was no gastric volvulus. The rest of the bowel was unremarkable. He underwent a stapled resection of the proximal stomach (**Figure 1**) with restoration of the bowel continuity by anastomosing the distal stomach with the oesophagus (**Figure 2**) and a feeding jejunostomy. He had an uneventful post-operative recovery with initial nutrition through the feeding jejunostomy for a week and subsequently started on oral feeds. He was discharged after three weeks. Histopathology revealed ischaemic gastropathy with no evidence of neoplastic pathology.

Figure 1: Resection of gangrenous proximal stomach

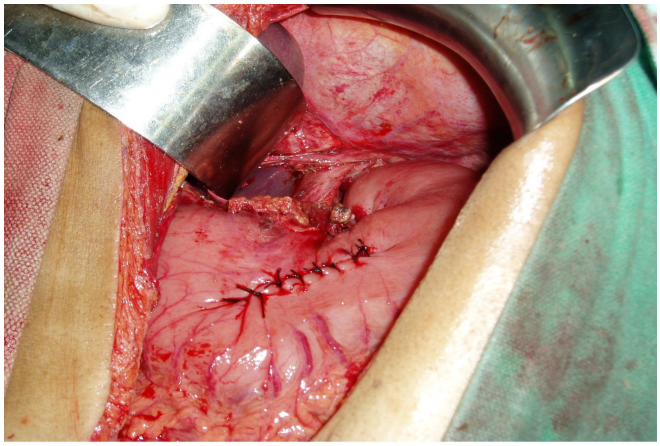

Figure 2: Anastomosed oesophagus to distal stomach

Discussion

Gastric necrosis and perforation are extremely uncommon because of a rich blood supply but when present can produce profound circulatory disturbance and death, particularly in the post operative period.[3] It is akin to paralytic ileus.

Various aetiologies leading to acute gastric dilatation which have been described include :Gastric outlet obstruction,retroperitoneal tumor involving duodenum,gastric volvulus, post abdominal surgery,trauma,diabetic ketoacidosis,anorexia nervosa,cerebral palsy / muscle dystrophy,diaphragmatic herniation,and psychogenic polyphagia

Some rarer causes include post variceal sclerotherapy, following percutaneous endoscopic gastrostomy, laparoscopic gastric banding and dissection of greater curvature.[4,5] Acute dilatation has been described in Prader-Willi syndrome possibly related to genetic abnormalities of gastric homeostsis.These patients are able to consume large quantities of food without vomiting.[6]

The clinical features of acute dilatation include epigastric fullness, tachycardia, abdominal hyper-resonance, nausea and vomiting (described as 'storm water of a peat laden stream') and succussion splash.

Several mechanisms have been postulated to explain the occurrence of acute gastric dilatation. In 1842, Von Rokitansky described superior mesenteric artery syndrome as a cause.[1,7,8] In 1859, Brinton proposed the atony theory, where the primary abnormality is loss of gastric tone secondary to reflex inhibition of gastric motor nerves causing relaxation of the upper oesophageal sphincter and subsequent aerophagia and gastric dilatation. Proximal gastrointestinal tract atony has also been attributed to electrolyte abnormalities such as hypokalemia and hypochloraemia.[1,7] Literature states that acute gastric dilatation in anorexic patients is caused by the development of a direct neurogenic paralysis secondary to malnutrition.[2]

The sequence of events that takes place after acute gastric dilatation include increasing intra-gastric pressure leading to gastric wall ischemia and perforation as well as pressure on the inferior venacava causing reduced venous return and hypotension. Early gastric dilatation can be managed conservatively with nasogastric aspiration, fluid resuscitation and correction of dyselectrolytemia. An upper GI endoscopy can be helpful and can decompress an acutely dilated stomach. A CT scan can pick up a retroperitoneal mass. Patients with

neurological disorders will require a feeding jejunostomy. In advanced cases surgery remains the only option with resection of the necrosed segment and reconstruction by anastomosing the esophageal end to the remaining stomach or the jejunum. Even in cases where early surgery is undertaken there is a reported mortality of 50-60%.[2]

MAJ. N TIWARI[1]
BRIG. AK SHARMA[2]
LT. COL. A GALAGALI[3]
WG. CDR. M KUMAR[3]
MAJ. K CHAND[4]

Military Hospital, CTC, Pune[1],
Army Hospital (R&R) New Delhi[2],
Armed Forces Medical College, Pune[3],
Military Hospital, Meerut[4]

Correspondence: Wing. Cdr. Manoj Kumar
Reader, Dept of Surgery
Armed Forces Medical College
Wanowrie PO, Pune – 411040, India.
Email: drmanojsurgeon@yahoo.co.in

References

1. Todd SR, Marshall GT, Tyroch AH. Acute gastric dilatation revisited. *Am Surg*. 2000;**66**:709–10.
2. Adbu RA, Garritano D, Culver O. Acute gastric necrosis in Anorexia Nervosa and Bulimia. *Arch Surg*. 1987;**122**:830–2.
3. Turan M, Sen M, Canbay E, Karadayi K, Yildiz E. Gastric necrosis and perforation caused by acute gastric dilatation: report of a case. *Surg Today*. 2003;**33**:302–4.
4. Bortul M, Scaramucci M, Tonello C, Spivach A, Liguori G. Gastric wall necrosis from organoaxial volvulus as a late complication of laparoscopic gastric banding. *Obes Surg*. 2004;**14**:285–7.
5. Michel LA, Buche M, de Canniere L, Chenu P. Gastric volvulus after coronary bypass. *Lancet.* 1997;**349**:251.
6. Wharton RH, Wang T, Graeme-Cook F, Briggs S, Cole RE. Acute idiopathic gastric dilation with gastric necrosis in individuals with Prader-Willi syndrome. *Am J Med Genet*. 1997;**73**:437–41.
7. Chaun H. Massive gastric dilatation of uncertain etiology. *CMAJ*. 1969;**100**:346–8.
8. Byrne JJ, Cahill JM. Acute gastric dilatation. *Am J Surg*. 1961;**101**:301–9.

Acute gastric volvulus and pancreatitis following abdominal trauma in a case of eventration of diaphragm

Introduction

We present a where mesenteroaxial gastric volvulus with acute pancreatitis presented as an epigastric lump following abdominal trauma in a child with occult left sided eventration of diaphragm. This case is worth reporting due to its rarity and to emphasize the wide range of rare presentation that eventration of diaphragm can produce.

Case report

A 6 year old female child presented to pediatric emergency with hemodynamic instability following blunt trauma to the upper abdomen 4 days back, due to fall over a stone while playing. There was history of violent cough following the trauma. Two days after the trauma she developed respiratory distress, abdominal distension and coffee ground vomiting. Abdominal distension was confined to upper abdomen. There was history of constipation for 4 days. There was no history of fever or urinary symptoms. No past history of abdominal or respiratory problems. Pediatricians made a clinical diagnosis of traumatic liver hematoma and pediatric surgical consultation was sought. General physical examination revealed pallor, severe dehydration, tachycardia with low volume pulse and tachypnea. Heart sounds were normal but left basal air entry was grossly diminished. Abdominal examination revealed a soft, tender and resonant epigastric mass with no visible peristalsis. Digital rectal examination was normal. The child was resuscitated and investigated with a presumptive diagnosis of traumatic pseudocyst of the pancreas. However passing a nasogastric tube was difficult, and had to be manipulated 4 times before 900 ml of coffee ground fluid could be aspirated. Erect X-ray abdomen (AXR) showed abnormal course of the nasogastric tube from anterior to posterior direction with tip reaching the left subcostal area (**Figure 1A**). There were two air fluid levels in left upper quadrant with no distal bowel gas. The left hemidiaphragm was intact but highly placed at the level of 5th rib, and there was no