AMEET KUMAR[1]
TS RAMAKRISHNAN[1]
ANIL BEHL[2]
SAMARESH SAHU[3]
GURDEEP SINGH[4]

Corresponding Author: Dr Ameet Kumar
Department of Surgery[1]
Dept. of Surgery, Command Hospital, Bangalore[2]
Department of Radiology[3]
Department of Pathology[4]
Air Force Hospital,
Nathu Singh Road, Kanpur Cantt, UP, India.
Email: docam@rediffmail.com

References

1. Rao PL, Sharma AK, Yadav K, Mitra SK, Pathak IC. Acute intestinal obstruction in children as seen in north west India. *Indian Pediatr*. 1978;**15**:1017–23.
2. Dimitrios C, George AA, Dimosthenis Z, Nikolaos X. Intestinal obstruction due to an anomalous congenital band. *Saudi J Gastroenterol*. 2008;**14**:36–7.
3. Khanzada TW, Samad A, Sushel C. Etiological spectrum of dynamic intestinal obstruction. *Gomal J Med Sci*. 2007;**5**:59–61.
4. Parashar UD, Holman RC, Cummings KC, Staggs NW, Curns AT, Zimmerman CM, et al. Trends in intussusceptions-associated hospitalizations and deaths among US infants. *Pediatrics*. 2000;**106**:1413–21.
5. Balthazar EJ, Birnbaum BA, Megibow AJ, Gordon RB, Whelan CA, Hulnick DH. Closed-loop and strangulating obstruction: CT signs. *Radiology*. 1992;**185**:769–75.
6. Ozenç A, Ozdemir A, Coskun T. Internal hernia in adults. *Int Surg*. 1998;**83**:167–70.
7. Sung TJ, Cho JW. Small bowel obstruction caused by an anomalous congenital band in an infant. *Korean J Pediatr*. 2008;**51**:219–21.
8. Akgur FM, Tanyel FC, Buyukpamukcu N, Hicsonmez A. Anomalous congenital bands causing intestinal obstruction in children. *J Pediatr Surg*. 1992;**27**:471–3.
9. Ko SF, Tiao MM, Huang FC, Hsieh CS, Huang CC, Ng SH, et al. Internal hernia associated with Meckel's diverticulum in 2 pediatric patients. *Am J Emerg Med*. 2008;**26**:86–90.
10. Kulacoglu H, Tumer H, Aktimur R, Kusdemir A. Internal Herniation with fatal outcome: herniation through an unusual apertura between epiploic appendices and greater omentum. *Acta Chir Belg*. 2006;**106**:109–111.
11. Wu JM, Lin HF, Chen KH, Tseng LM, Huang SH. Laparoscopic diagnosis and treatment of acute small bowel obstruction resulting from a congenital band. *Surg Laparosc Endosc Percutan Tech*. 2005;**15**:294–6.

Eosinophilic enteritis-A rare case of chronic diarrhoea in a child

Introduction

Eosinophilic enteritis (EE) is a rare disease that is characterized by tissue eosinophilia. The clinical signs and symptoms depend on the layer of the gut predominantly involved. Klein and Tally et al. have classified this disorder into mucosal, submucosal and subserosal disease, based on the layer of the gut predominantly involved.[1-3] The most prevalent form is the one with predominant involvement of the mucosal layer with symptoms of colicky abdominal pain, nausea, vomiting, diarrhoea and weight loss. The exact pathogenesis of the disease remains unknown but, at least in some of these patients with predominant involvement of the mucous layer, high serum IgE levels has been documented. Most patients will have history of food allergy or family history of allergy.[4]

Case Report

A six year old female child born of non consanguineous parents was admitted with a history of abdominal distension with vague pain and loose stools of two months duration. She had 6-8 loose motions per day associated with borborygmi with occasional vomiting. She had loss of appetite with low grade intermittent fever. There was no history of contact with open case of tuberculosis, drug intake, or worm infestation. Physical examination revealed grade I protein malnutrition, mild anemia and pedal edema. Abdomen was distended with a doughy feel. Investigations revealed a total count of 14,800 cells/cu mm, differential count of 20% polymorph, 28% lymphocytes, 52% eosinophils. Hemoglobin was 9 gm% and peripheral smear showed hypochromic microcytic anemia. Stool examination showed no ova or cysts. Occult blood was negative. Serum albumin was 3 gm/dl. Chest X ray was normal. HIV test and mantoux tests were negative. Ultrasound (USG) abdomen revealed minimal free fluid with thickened bowel wall. Barium meal follow through showed thickened bowel wall with features suggestive of malabsorption. Upper gastrointestinal endoscopy showed no visible abnormality and duodenal biopsy of the mucosa from the 3rd part of duodenum was done. Histopathology showed partial villous atrophy, intra epithelial infiltration with lymphocytes and dense tissue eosinophilia of more than 50/HPF (**Figure 1**). She had elevated serum IgE levels (196 IU/l). A final diagnosis of eosinophilic enteritis was

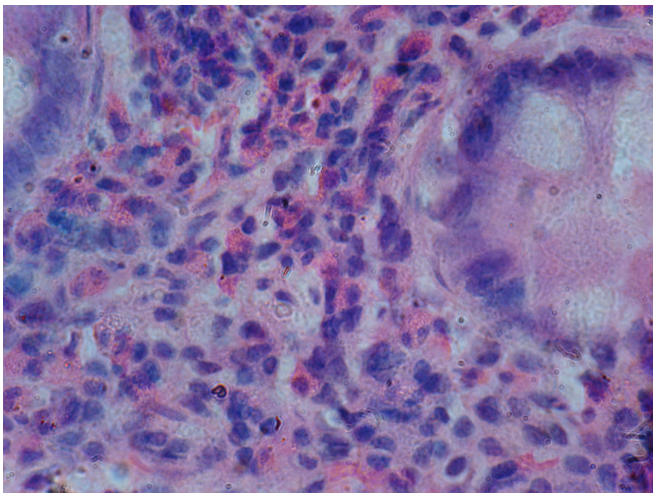

Figure 1: Photomicrograph of duodenal biopsy specimen stained with hematoxylin and eosin stains showing partial villous atrophy, intra epithelial infiltration with lymphocytes and dense tissue eosinophilia of more than 50/HPF

made. Our patient had involvement of mucosal and subserosal involvement as she had diarrhoea and ascites. . The child was started on oral prednisolone 2mg/kg and tapered over a period of three months. The child showed dramatic response to oral steroid therapy. The child improved clinically with reduction in diarrhoeal frequency and gain in weight. Currently the child is doing well.

Discussion

Chronic diarrhoea in children encompasses a wide variety of causes. When our patient presented with diarrhoea for two months duration, the initial evaluation was carried to rule out some of the conditions peculiar to tropical countries like giardiasis, tuberculosis and persistent infectious diarrhoea. She had peripheral eosinophilia. Upper gastroscopy with duodenal biopsy confirmed the diagnosis of EE. Elevated serum IgE is seen more often in paediatric population than adults with EE.[5] Eosinophilic enteritis is an uncommon disorder that has been documented mainly in adulthood[3] and characterized by infiltration by eosinophils of gastrointestinal tract. Patients with mucosal involvement present with nausea, vomiting, diarrhoea and weight loss. Muscular involvement usually presents with intermittent obstructive symptoms or with complications like perforation. Serosal involvement presents with ascites. Rarely, other organs like pleura, pericardium, gall bladder, biliary tree and liver can be affected. The exact etiology is not known although few of these patients may have food allergy or family history of allergy. Canine hookworm, Ankylostoma infestation, drugs like carbamazepine, cotrimoxazole and heavy metals like gold have been incriminated as causes in enterocolitis with tissue eosinophilia. The defects in mucosal integrity may be responsible for localization of various antigens in gut wall resulting in infiltration of eosinophilia in blood and tissues. Favourable response to steroids suggest the possibility of type I hypersensitivity reaction. Eosinophil through toxic cationic protein (MBP) plays a role in pathogenesis of this disease.[3] Food allergy has been noticed in 50% of cases.[6]

Allergic mechanism has been implicated in most of these patients.[7] A viral etiology has also been suggested in some cases.[8] Peripheral eosinophilia is noticed in 80% of patients.[2] The diagnosis is established by demonstration of tissue eosinophilia on endoscopic, laparoscopic or surgical specimens. However, the endoscopy may be normal or may show mild erythema to nodularity, thickened mucosal folds or even frank ulcerations. Full thickness surgical biopsies may be needed for diagnosis if the disease process is confined to the muscular layer. Ultrasonography, barium contrast studies, computerised tomography of the abdomen may show bowel thickening, nodularity or evidence of gastric outlet obstruction. Stomach is the most common site.[2] Duodenum and rest of the small bowel may be involved.[9] Steroids form the mainstay of therapy and nearly 90% will show favourable response. Mast cell stabilizers like sodium chromoglycate can be used to prevent mast cell degradation and release of histamines and leukotrines. Eosinophilic gastroenteritis in general has good prognosis.

B. SUMATHI[1]
D NIRMALA[1]
B. BHASKAR RAJU[1]
V RAJALAKSHMI[2]

Corresponding author: Dr. B. Sumathi
Dept. of Pediatric Gastroenterology[1] and Pathology,[2]
Institute of child Health & Hospital for Children,
Egmore, Chennai-8, Tamilnadu, India
Email: drbsumathi@rediffmail.com

References

1. Klein NC, Hargrove RL, Sleisenger MH, Jeffries GH. Eosinophilic gastroenteritis. *Medicine*. 1970;**49**:299–319.
2. Talley NJ, Shorter RJ, Philips SF, Zinsmeister AR. Eosinophilic Gastroenteritis: a clinicopathological study of patients with disease of mucosa, muscular layer and subserosal tissues. *Gut*.

1990:**31**:54–8.

3. Talley NJ, Kephart GM, McGovern TW, Carpenter HA, Gleich GJ. Depsosition of eosinophil granule major basic protein in eosinophilic gastroenteritis and celiac disease. *Gastroenterology*. 1992;**103**:137–45.
4. Zora JA, O'Connell EJ, Sachs MI, Hoffman AD. Eosinophilic gastroenteritis: a case report and review of the literature. *Ann Allergy*. 1984;**53**:45–7.
5. Katz AJ, Goldman H, Grand RJ. Gastric mucosal biopsy in eosinophilic (allegic) gastroenteritis. *Gastroenterology*. 1977;**73**:705–9.
6. Scudamore HH, Phillips SF, Swedlund HA, Gleich GJ. Food allergy manifested by eosinophilia, elevated immunoglobulin E level and protein losing enteropathy: the syndrome of allergic gastroenteropathy. *J Aller Clin Immunol*. 1982;**70**:129–38.
7. Khan S. Eosinophilic gastroenteritis. *Best Pract Res Clin Gastroenterol*. 2005;**19**:177–98.
8. Whitington PF, Whitington GL. Eosinophilic gastroenteropathy in childhood. *J Pediatr Gastroenterol Nutr*. 1988;**7**:379–85.
9. Naylor AR. Eosinophilic gastroenteritis. *Scott Med J*. 1990;**35**:163–5.

Blunt abdominal trauma, acute mesenteric venous thrombosis and small bowel stricture

Introduction

Thrombosis of the portal vein (PV) or its tributaries following blunt abdominal trauma is very rare and most of the reported cases of injury to the portal venous system have been the result of penetrating wounds. Further portal vein thrombosis after blunt abdominal trauma, which is followed by intestinal obstruction, has not been previously reported. We present what we think is the first such case.

Case Report

A 43-year-old army officer presented with a history of having had a road traffic accident when the car he was driving was hit by a truck. He lost consciousness for a few minutes and after being taken to a casualty department underwent computerized tomograpy (CT) of the head which was normal. He also had abdominal pain and a CT scan of the abdomen was done at the same time which was also normal. He was managed conservatively and discharged after four days. He remained well for one week after which he started having recurrent episodes of colicky abdominal pain, vomiting and obstipation. He was investigated with another CT scan of the abdomen with oral (water) and intravenous contrast which showed an altered echotexture of the liver with an occlusive fresh thrombus involving the PV, extending into its right branch and proximally into the superior mesenteric vein (SMV) (**Figure 1&2**). There was luminal narrowing of the distal small bowel with proximal dilatation, suggestive of an ischaemic stricture (**Figure 3**). There was no evidence of any other visceral injury. He was referred to our unit for further management. His complete blood counts, liver function tests, renal function tests and procoagulant screening were all within normal limits. Upper gastrointestinal

Figure 1: CT scan of the abdomen showing hypodense thrombus in the lumen of the portal vein extending into superior mesenteric vein.

Figure 2: CT scan showing thrombus in the right PV