causes its enlargement. Thus, at center of appendix epiploica there is calcification surrounded by thick laminated fibrinoid material. In present case, the histopathology showed thick laminated hyaline wall with inner layers showing diffuse granular calcification. Takada et al[6] and Nomura et al[7] preoperatively suspected loose peritoneal body as calcified leiomyoma. The loose peritoneal bodies are of variable sizes and number, arise as a result of chronic process. Mohri et al[8] reported a giant loose peritoneal body of size 9.5cm.They mentioned that the body has increased in size from 7.3 cm to 9.5 cm in the span of 5years. Peritoneum reacts by depositing fibrinoid material over it and it goes on increasing in size. Loose peritoneal body may give rise to no definite symptoms or may present with various symptoms like low abdominal pain or constipation[3] or even may present as acute retention of urine.[9] Many times they are found incidentally at laparotomy or in a cadaver.[3]

In the present case, patient had chronic constipation leading to hemorrhoids and these symptoms were relieved after surgery .So, we suspect that the loose peritoneal body may be causing pressure on rectum intermittently. Probably, because of its weight (108gms in present case) and smooth surface it might be getting lodged in pelvis intermittently giving rise to above symptoms.

J.B. HEDAWOO
AMIT WAGH

Department of Surgery
Government Medical College,
Nagpur. Maharashtra
Email: amitwagh50@gmail.com

References

1. Harrigan AH. Torsion and inflammation of the appendix epiploicae. Ann Surg. 1917;66:467–78.
2. Borg SA, Whitehouse GH, Griffiths GJ. A mobile calcified amputed appendix epiploica. Am J Rentogenol. 1976;127:349–50.
3. Ross JA, McQueen A. Peritoneal loose bodies. British J Surg. 1947/48;35:313–7.
4. Hunt VC: Torsion of appendices epiploicae. Ann Surg. 1919;69:31–46.
5. Patterson DC. Appedices epiploicae. N Engl J Med. 1933;209:1255–9.
6. Takada A, Moriya Y, Muramatsu Y, Sagae T. A case of giant peritoneal loose bodies mimicking calcified leiomyoma originating from the rectum. Jpn J Clin Oncol. 1998;28:441–2.
7. Nomura H, Hata F, Yasoshima T, Kuwahara S, Naohara T, Nishimori H, et.al. Giant loose peritoneal body in pelvic cavity:Report of case. Surg Today. 2003;33:791–3.
8. Mohri T, Kato T, Suzuki H. A giant peritoneal loose body: report of a case. Am Surg. 2007;73:895–6.
9. Bhandarwar AH, Desai VV, Gajbhiye RN, Deshraj BP. Acute retention of urine due to a loose peritoneal body. Br J Urol. 1996;78:951–2.

Rapunzel syndrome: report of a case with review of treatment

Introduction

"Rapunzel" is a German fairy tale assembled by the Brothers Grimm with its well known line "Rapunzel, Rapunzel, let down your hair, so that I may climb the golden stair".[1] Rapunzel syndrome is a rare disorder caused by accumulation of large amounts of ingested hair in the stomach with a tail extending into the small or large bowel.[2]

Case report

A 15-year-old girl presented with history epigastric discomfort, with a lump in her abdomen. On examination, she had a well defined, nontender, firm, mobile mass in the upper abdomen. There was an area of non-scaring alopecia measuring 3 x 3 cm in the frontal region of her scalp. Computed tomography showed a free floating mass in the stomach. Upper endoscopy showed a large hair ball occupying the entire stomach with extension beyond pylorus and hence the diagnosis of Rapunzel syndrome was made (Fig 1). Endoscopic therapy was not attempted as the hair ball was large and was made of tight coils of long hair with extension beyond the pylorus. Laparotomy was done and entire trichobezoar was removed by anterior gastrotomy (Fig 2 a and b). Postoperative recovery was uneventful. She underwent psychiatric evaluation and was found to have subclinical depression and trichotillomania with trichophagia, for which she was started on desipramine, a tricyclic antidepressant. She was healthy with no recurrence of symptoms at one year follow-up.

Discussion

Bezoars are formed when the ingested foreign material or organic matter forms a mass in the gut, usually in stomach of patients with outlet obstruction or motility disorder. Trichobezoar is formed by concretions of hair ingested over period of years. Rapunzel syndrome is rare variant of trichobezoar which has a large gastric hair ball and a tail extending across the pylorus into the small or large bowel.[2] Ingested hair is not digested and the smooth slippery surface of hair does not allow for its propulsion through peristalsis. Thus, hair gets trapped in the stomach and increases in size as more hair is added, the resulting mass stops peristalsis of the stomach completely.[2,3] Usually, there is no obstruction of the gastrointestinal tract. In this girl, a large hair ball occupied the entire stomach with a tail into the duodenum.

Patients can present with malnutrition, weight loss, and abdominal pain with signs of gastrointestinal obstruction or perforation.[3] They have trichotillomania, compulsive hair pulling and trichophagia, eating their hair.[4] Trichotillomania was first described in 1889 by French dermatologist Hallopeau and its prevalence is 0.6%–1.6% by DSM-IV criteria. Only 30% of those with trichotillomania will engage in trichophagia and of these, only 1% will go on to eat their hair to the extent requiring surgical removal.[4] Trichotillomania is far more common in girls than boys and has bimodal age distribution. Early onset hair pulling (before 8 years) is benign

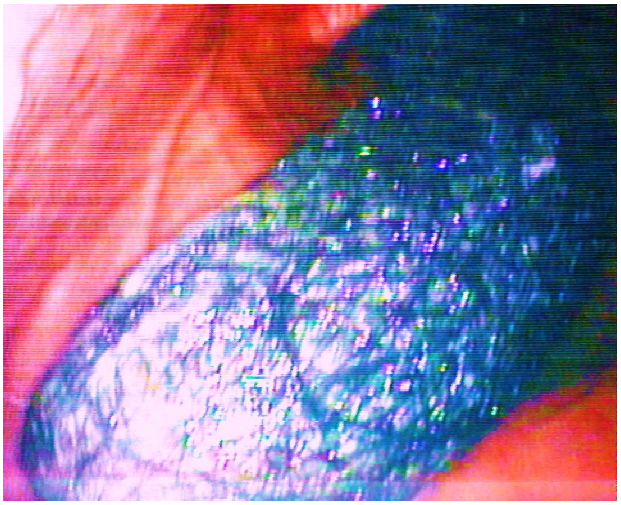

Figure 1: Gastroscopy showing a large trichobezoar with extension seen going beyond pylorus

Figure 2a: The hairball been extracted through the gastrotomy

Figure 2b: Specimen of the Rapunzel syndrome with large body in the shape of stomach with a tail that was extending into the duodenum.

and self limited. That occurring in the later in adolescence is more likely to be chronic and accompanied by comorbid psychiatric disorders, such as depression, anxiety, obsessive-compulsive disorder, body dysmorphic disorder, eating disorders, and alcohol and substance abuse.[5] The present patient was diagnosed with subclinical depression and compulsive hair pulling with trichophagia.

Smaller trichobezoars can be removed endoscopiscally after fragmentation by water pick, laser, or extracorporeal shock-wave lithotripsy or dissolved enzymatically. Laparoscopic removal of small bezoars is also done. However, very large ones require removal through open gastrotomy as required in this patient.[6-8] Common treatment modalities of trichotillomania include medication and cognitive behavior therapy - habit-reversal training.[5] Treatment of the underlying psychiatric disease is necessary to prevent recurrence of trichobezoar.[9]

MUTHUKUMARASSAMY RAJAKANNU
VENKATESHWARLU

Correspondence:Dr. Muthukumarassamy Rajakannu
Indira Gandhi Government General Hospital and Postgraduate Institute
Victore Simonel Street,
Pondicherry, India
Email: muthukumarassamy@yahoo.com

References

1. Grimm Brothers: Rapunzel. Translated by Godwin-Jones R. Richmond, Virginia Commonwealth University Department of Foreign Languages, 1994–1999.
2. Rabie ME, Arishi AR, Khan A, Ageely H, Seif El-Nasr GA, Fagihi M. Rapunzel syndrome: the unsuspected culprit. World J Gastroenterol. 2008;14:1141–3.
3. Birmingham CL, Gritzner S. Gastric bezoar in anorexia nervosa. Eat Weight Disord. 2007;12:e28–9.
4. Bouwer C, Stein DJ. Trichobezoars in trichotillomania: case report and literature overview. Psychosom Med. 1998;60:658–60.
5. Walsh KH, McDougle CJ. Trichotillomania. Presentation, etiology, diagnosis, and therapy. Am J Clin Dermatol. 2001;2:327–333.
6. Nirasawa Y, Mori T, Ito Y, Tanaka H, Seki N, Atomi Y. Laparoscopic removal of a large gastric trichobezoar. J Pediatr Surg. 1998;33:663–5.
7. De Backer A, Van Nooten V, Vandenplas Y. Huge gastric trichobezoar in a 10-year-old girl: case report with emphasis on endoscopy in diagnosis and therapy. J Pediatr Gastroenterol Nutr. 1999;28:513–5.
8. Narci A, Sen TA. Treatment of Rapunzel Syndrome - Gastrostomy or Gastrotomy? Dig Surg. 2008;25:80.
9. Ratnagiri R, Smile SR, Sistla SC. Recurrent gastric trichobezoar. Indian J Gastroenterol. 2002;21:229–30.