Case Reports

Human Intestinal Capillariasis: A Rare Cause of Chronic Diarrhoea In India

Sandhra Papparath Usman[1]
Sojan George Kunnathuparambil[2]
Deepti Ramakrishnan[1]
Joy Augustine[1]
Kundoly V Susheela[3]

[1]Department of Pathology, [2]Department of Gastroenterology, [3]Department of Microbiology, Amala Institute of Medical Sciences, Amalanagar, Thrissur-680555, Kerela, India.

Corresponding Author: *Dr Sandhra Papparath Usman*
Email: snu.usman@gmail.com

Human intestinal capilliariasis is a disease endemic to the Philippines and Thailand[1,2]. The disease causing agent, *Capillaria philippinensis* is an intestinal nematode belonging to the superfamily, Trichinelloidae. Infection ensues as a result of ingestion of raw or insufficiently cooked fish, harboring larvae. Small intestine, especially the jejunum is usually the affected organ, resulting in chronic diarrhea, malabsorption, abdominal pain and borborgymi. It may be misdiagnosed as malabsorption disorder in non-endemic areas, especially since the eggs are excreted sporadically in feces and maybe missed unless multiple samples are examined. Microscopic examination of jejunal biopsy and aspirated content may help establish the diagnosis. India is non endemic for *C. philippinensis* infestation. To our knowledge, this is the fourth reported case of *Capillariasis* from India.

Case Report

A 34 year old male presented with an 8 month history of chronic watery diarrhea, associated with right iliac fossa pain. He also experienced loss of appetite and weight loss of over 20 kilograms over the last 8 months.

There was no history of recent travel. The patient was a non-vegetarian and had a history of frequenting roadside stalls serving shell fish and mussels. The patient was also an alcoholic.

On examination, he had hypotension (68/40 mm Hg in the right upper limb) and Bilateral pitting pedal oedema. Abdominal examination revealed diffuse tenderness with no organomegaly.

His haemogram and RFT were within normal limits. However, he had hypoalbuminemia (1.4 g/dL) and hypokalemia (serum potassium: 2.4mmol/L) with a CRP value of 15.6mg/L. Ultrasound abdomen and CT abdomen showed features of which could possibly suggest an Inflammatory Bowel disease. Colonoscopic imaging revealed edematous mucosa in the caecum and ascending colon with a healed ulcer in the ileum, from which biopsies were taken.

Histopathological examination of biopsy taken from the ileum and caecum showed moderate degree of chronic inflammation with focal flattening of villi and body parts of nematode parasite.

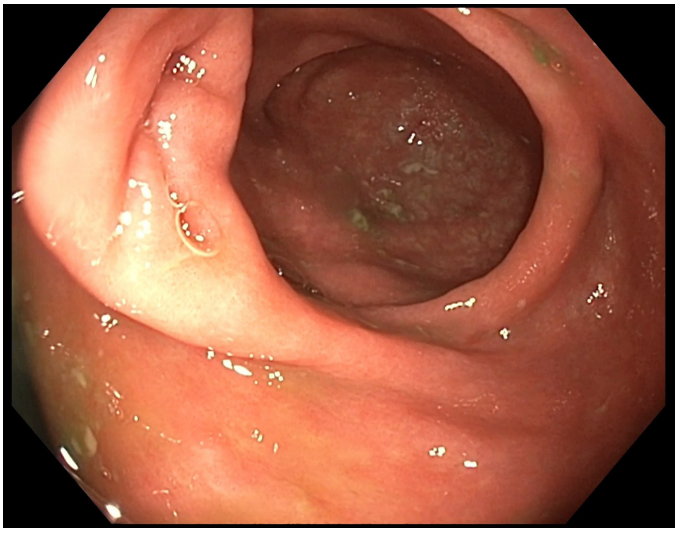

Figure 1: Oedematous mucosa in caecum.

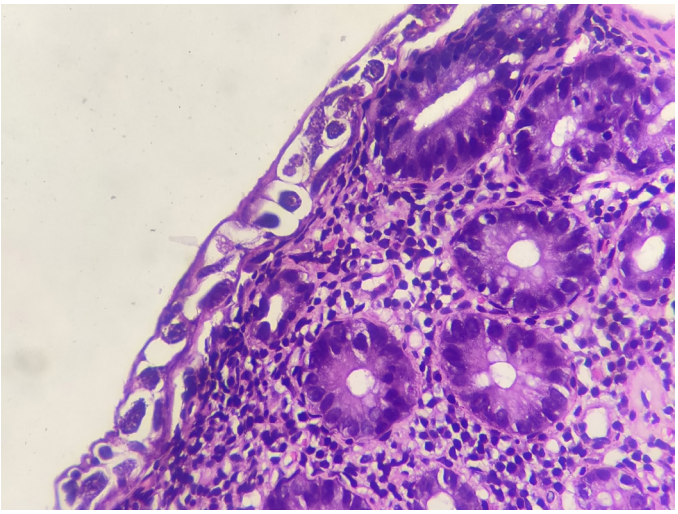

Figure 2: HPE 40X Colonic mucosa with nematode on surface.

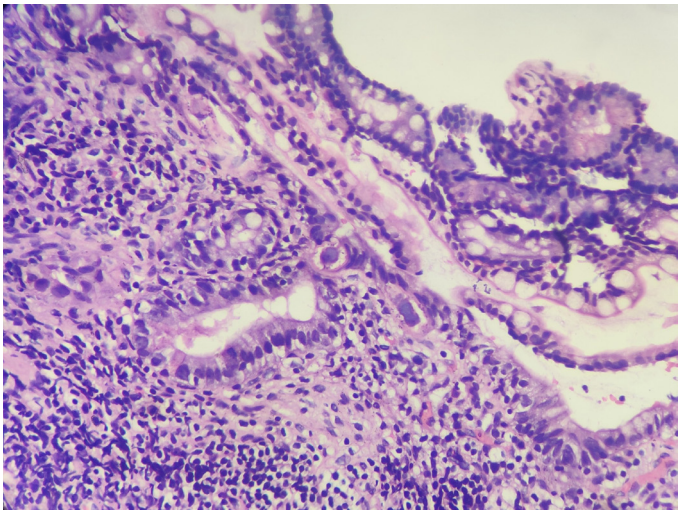

Figure 3: HPE 40X Colonic mucosa with nematode within colonic mucosal glands.

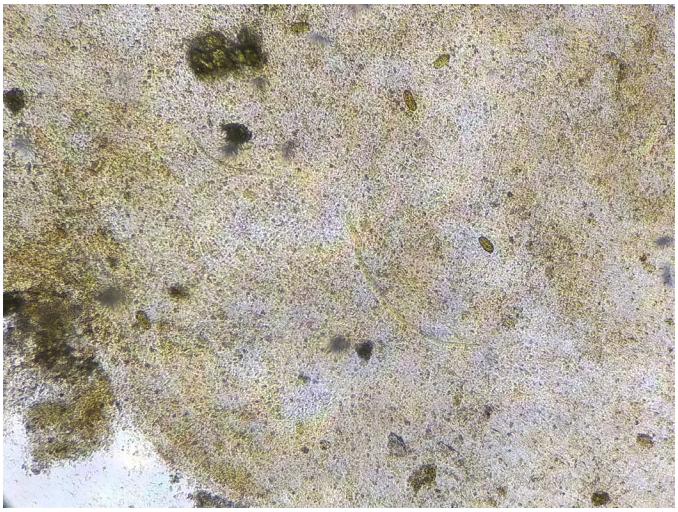

Figure 4: Wet mount preparation of stool showing a Larval forms of Capillaria philippinensis.

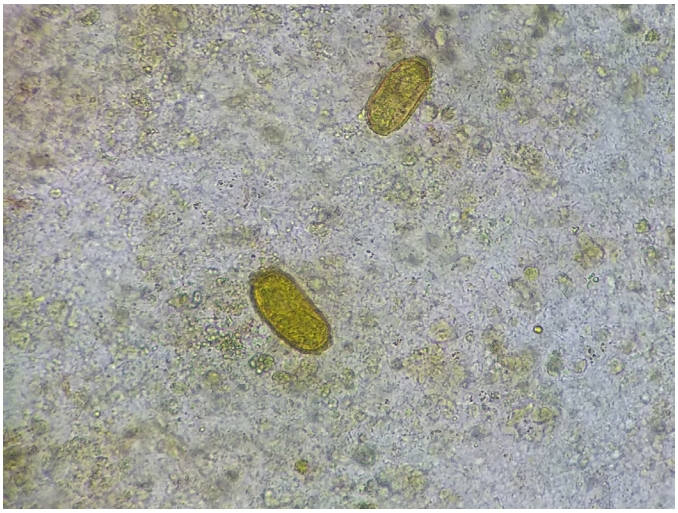

Figure 5: Wet mount preparation of stool showing Ova of Capillaria philippinensis.

The stool sample microscopy showed plenty of bile stained barrel and oval shaped ova with mucous plugs. These features were consistent with *Capillaria philippinensis*.

A diagnosis of Intestinal capillariasis was made and the patient was treated with Albendazole (400 mg) a day for 10 days along with correction of fluid and electrolyte imbalance. Dietary advice was given.

On follow up after one month, diarrhoea had subsided. Weight gain of 11 kgs was noted. Stool examination did not show any ova.

Discussion

Capillaria philippinensis is a nematode belonging to the superfamily, Trichinelloidae, which include the genera Trichuris, Trichinella and Capillaria[2]. In humans, it is responsible for Intestinal capillariasis, which was first reported in the Philippines in 1964. Consequently many sporadic cases have been recorded in Thailand as well, making these two nations endemic for the disease. Further, non endemic countries like Japan, Iran, Indonesia, Taiwan, Egypt, Spain and Italy have

also reported cases of Intestinal capillariasis[3]. In India, the first case was reported in a 45 year old female patient in the year 1994, by Kang *et al*. from Vellore[4]. Following this, 2 more cases have been reported[5,6].

Human infection occurs as a consequence of ingesting fresh water fish which harbor the infective stage of the parasite the larval stage. Fish-eating birds are the natural definite hosts, within the intestines of which the adult worms release embryonated eggs. These may be dispersed in water bodies through bird droppings, where they further infect fish. Naturally infested fish include Hypseleotris bipartite and Apagon species and naturally infected birds include Ixobrychus species[7].

In experimental studies done in Mongolian gerbils and some monkeys, the phenomenon of auto infection by *C. philippinensis* was established. By this phenomenon, offsprings of adult worms are capable of reinfesting the same host, allowing it to multiply within a single host. This can lead to hyperinfection[8].

The adult worms cause infection by penetrating the mucosa of small intestine and reentering the lumen. Over time, the mucosa and submucosa may degenerate. As a result, infected individuals have abdominal pains, diarrhea, weight loss, malaise, anorexia and emaciation. Loss of proteins and electrolytes and malabsorption of fat and sugars occur. Patients usually have hypokalaemia and hypoalbuminaemia[9]. Biopsy of small intestine usually show atrophied crypts, flattened villi, and leukocyte infiltration that are indicative of intestinal cell injury. If left untreated, it may prove to be fatal.

In our case, the patient may have acquired the disease by ingestion of endemic fresh water and brackish water fish capable of harbouring the worm such as Anabas species. He showed features of diarrhea, abdominal pain and weight loss, possibly due to malabsorption. Pedal oedema may have developed due to hypoalbuminemia. The patient had no travel history and may have contracted the disease by ingestion of under cooked fish, which was part of his diet. Since India is non-endemic for *C. philippinensis*, the disease may be traced back to infection carrying migratory fish-eating birds from endemic areas.

Diagnosis can be made by simple wet mount examination of stool sample and identification of ova, larvae and adult worms. The ova of Capillaria can be distinguished from that of Trichuris trichura by its peanut shaped appearance, flattened mucous plugs and striations shell[1]. Trichuris ova have prominent mucoid bipolar plugs. Adult male worms are shorter (1.5-3.9 mm) than female worms (2.3 - 5.3 mm). They have a muscular oesophagus called stichosome, surrounded by stichocytes. Male worms have single sheathed spicule. Female worms have uterus with numerous thick and thin shelled eggs. The eggs may be with or without larvae. Larvae in stool sample are difficult to be identified as *C. philippinensis* due to its resemblance to developmental forms of other nematodes.

The eggs of *C. philippinensis* are excreted sporadically and hence multiple stool samples may be required to establish diagnosis. Immunodiagnosis may help diagnose the disease before eggs or larvae are identified in the stool[1].

Conclusion

C. philippinensis, although non endemic to India, has to be considered in the diagnosis of patients with chronic diarrhea and malabsorption since it may prove fatal if left untreated. If detected, a thorough epidemiological study need to be conducted to detect the source and prevent further transmission. It is also important to encourage proper cooking of fish before consumption.

References

1. Cross JH. Intestinal capillariasis [Internet]. Vol. 5, Clinical Microbiology Reviews. Clin Microbiol Rev; 1992. p. 120-9.
2. Saichua P, Nithikathkul C, Kaewpitoon N. Human intestinal capillariasis in Thailand. Vol. 14, World Journal of Gastroenterology. World J Gastroenterol; 2008. p. 506–10.
3. Bair MJ, Hwang KP, Wang TE, Liou TC, Lin SC, Kao CR, *et al*. Clinical features of human intestinal capillariasis in Taiwan. World J Gastroenterol. 2004 Aug 15;10(16):2391–3.
4. Kang G, Mathan M, Ramakrishna BS, Mathai E, Sarada V. Human intestinal capillariasis: first report from India. Trans R Soc Trop Med Hyg. 1994 Mar ;88(2):204.

5. Rana SS, Bhasin DK, Bhatti HS, Gupta K, Gupta R, Nada R, *et al*. Human intestinal capillariasis: diagnosis by jejunal fluid analysis obtained at enteroscopy and reversal of subtotal villous atrophy after treatment. Endoscopy. 2009;41 Suppl 2:E102-3.
6. Vasantha P, Leela Ks, Girish N. Human intestinal capillariasis: A rare case report from non-endemic area (Andhra Pradesh, India). Indian J Med Microbiol. 2012;30(2):236.
7. Cross JH, Basaca-Sevilla V. Experimental transmission of Capillaria philippinensis to birds. Trans R Soc Trop Med Hyg. 1983;77(4):511–4.
8. Cross JH, Banzon T, Singson C. Further studies on Capillaria philippinensis: development of the parasite in the Mongolian gerbil. J Parasitol. 1978;64(2):208–13.
9. Chunlertrith K, Mairiang P, Sukeepaisarnjaroen W. Intestinal capillariasis: A cause of chronic diarrhea and hypoalbuminemia. Southeast Asian J Trop Med Public Health. 1992 ;23(3):433–6.

Managing *Clostridium Difficile* Infection Induced Persistent Toxic Megacolon with Prucalopride

Ajay Kumar Jain[1]
Suchita Jain[2]
Priyanka Bhagat[3]
Amit D Joshi[1]
Shohini Sircar[1]

[1]Department of Gastroenterology, [2]Department of Radio-diagnosis & Imaging, [3]Department of Pathology, Choithram Hospital & Research Centre, Indore (MP)-452014, India.

Corresponding Author: *Dr Ajay Kumar Jain*
Email: ajayvjain@yahoo.com

Toxic megacolon is a severe complication of *Clostridium difficile* infection (CDI) and is seen in about 8% of pseudomembranous colitis patients. The clinical manifestations of toxic megacolon are shock and severe ileus with or without diarrhoea. However, patients with no prior illness and no antibiotic exposure rarely present with toxic megacolon with community-acquired CDI. We present a case of toxic megacolon who had no exposure to antibiotics in the last six months without any comorbidities. Further, this community-acquired CDI with dilated colon persisted for almost ten days and was managed successfully with medical management using 5-Hydroxy-tryptamine receptor 4 (5HT4) agonist.

Case Report

A 38-year-old male, without any comorbidities presented with complaints of abdominal pain and distention of 8 days duration without any history of vomiting, diarrhoea, blood in stools, or weight loss. There was no history of any prior antibiotic exposure in the last six months. On admission, his temperature was 101.4^{0}F, and pulse rate was 110/min regular. His abdomen was distended with a tympanic note without any evidence of free fluid. Bowel sounds were sluggish. His hemogram showed Hb of 8.6g/dl, total WBC count of 18400 with 85% polymorphs and 10% lymphocytes platelet count of 4.5 lakhs/dl. Stool analysis showed multiple WBCs and RBCs. Erect skiagram of the abdomen showed a massively dilated colon with a maximum diameter of 7.3 cm (**Figure 1-A**). Contrast-enhanced CT of the abdomen revealed massively dilated transverse colon (7-7.5 cm) and ascending colon (6.5 cm) with loss of haustral markings (**Figure 2**). He was started with conservative management. In the next 24-48 hours, his pain in abdomen decreased; however, abdomen continued to remain bloated with a tympanic note. There was no decrease in the size of dilated loops of the colon on plain skiagram of the abdomen. There was

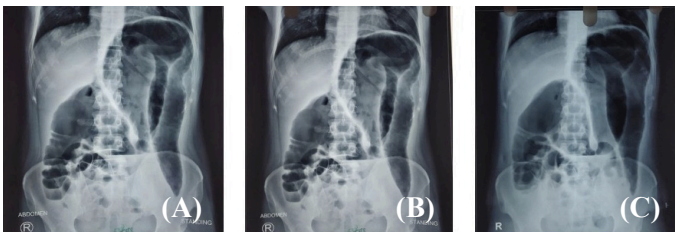

Figure 1: Plain X-ray abdomen showing Megacolon (A): on day 1; (B): on day 5; (C): on day 10.