in those cases were significantly higher(>1150 mg/l) requiring secondary detoxification by hemo-perfusion. This was unlike in our case where valproate levels were only marginally increased above therapeutic levels. Valproate toxicity is also associated with prolonged QTc interval in ECG, while in our case, the QTc was normal. Therefore AET due to valproate toxicity is unlikely in our case.

A few cases of hepatitis E with myocarditis have been reported[5]. Among these is a case of a 26-year-old male patient with acute viral hepatitis E who developed symptomatic myocarditis without any significant arrhythmias. Complex atrial tachycardias have also been reported with other viral infections like respiratory syncytial virus and enteroviral infections in infants.

The temporal sequence of events and the natural course of illness as discussed above made us conclude that acute Hepatitis E virus was the cause of self-limiting AET with AV conduction block with poor myocardial function in our case along with acute fulminant hepatitis. Despite our sincere efforts in searching medical literature available to us, we could not find similar cases of AET caused by hepatitis E virus. Thus, we can say that AET caused by hepatitis E virus in our case is a novel finding that has never been reported before. The question of whether valproate contributed to the existing hepatic dysfunction due to hepatitis E remains unanswered.

References

1. Walsh WP, Berul CI, Triedman JK. Cardiac Arrhythmias. In: Keane JF, Lock JE, Fyler DC, editors. Nadas' Pediatric Cardiology. 2nd ed. Philadelphia (PA): Elsevier Inc; 2006.
2. Hayashi J, Kashiwagi S, Okeda T, Okamura H, Ishibashi H, Hiramatsu Y, Fujino T *et al*. Electrocardiographic changes related to hypersecretion of catecholamine in a patient with fulminant hepatitis. Jpn J Med. 1988; 27:187-90.
3. Ursell PC, Habib A, Sharma P, Mesa-Tejada R, Lefkowitch JH, Fenoglio JJ Jr *et al*.Hepatitis B virus and myocarditis. Hum Pathol. 1984 May; 15(5):481-4.
4. Moreshwar S Desai, Daniel J Penny.Bile acids induce arrhythmias: old metabolite, new tricks.Heart. 2013; 99: 1629–30.
5. M. Premkumar, Devraja Rangegowda, Chitranshu Vashishtha *et al*. Acute Viral Hepatitis E Is Associated with the Development of Myocarditis. Case Reports in Hepatology. 2015 (2015), Article ID 458056, 6 pages.

Capillaria Hepatica: Report from North India

Sunayana Misra[1]
Pamali Nanda[2]
Devki Nandan[2]
Puja Sakhuja[2]

[1]Department of Pathology, GB Pant Institute of Post Graduate Medical Education and Research Delhi, India.
[2]Department of Paediatrics, PGIMER, Delhi, India.

Corresponding Author: *Dr Puja Sakhuja*
Email: pujasak@gmail.com

Capillaria hepatica (*C. hepatica*) is a nematode belonging to the family Trichocephalidea and class Trichuroidea[1]. First described by Bancroft in 1893[2], it infects primarily rodents; how ever it can affect over 140 mammalian species, including humans[3]. *C. hepatica* has a global distribution but the prevalence of human infection is extremely low with less than 75 cases of true infection being reported worldwide[3]. The most common symptoms include fever, hepatomegaly and eosinophilia thereby having a number of clinical differential diagnoses.

Children in developing countries belonging to a low socio-economic background are particularly vulnerable to developing infection with *C. hepatica* due to substandard hygienic conditions. A heavy parasitic load can lead to increased morbidity and even mortality due to hepatic failure. A timely liver biopsy and diagnosis by histopathology can be life saving. We report the second case of *C. hepatica* from North India in a paediatric patient diagnosed with the help of liver biopsy.

Case Report

An eighteen month old girl, resident of Dumri village, Bihar, India, presented with high grade fever and abdominal distension for two months. There was progressive loss of weight and appetite from the onset of the illness. At that time, the patient received ayurvedic medication from a local village doctor for two weeks.

There was no history of pain abdomen, vomiting, yellowish discoloration of the eyes, high-coloured urine or passage of worms in stool. On examination, she had a temperature of 103° F and severe pallor. The abdomen was soft with palpable liver and spleen, 8 cm and 2 cm below the right and left costal margins, respectively.

Laboratory investigations revealed severe microcytic hypochromic anaemia (haemoglobin of 6 g/dl), leucocytosis (26.7 X 109/L) with 33% eosinophils (absolute eosinophil count (AEC) was 8.8 X 109/L). The patient's erythrocyte sedimentation rate (ESR) was raised (45 mm/h). Liver function tests were normal. A bone marrow examination showed erythroid hyperplasia and increase in eosinophilic precursors. Bone marrow and blood cultures were sterile. Chest X-ray and urine and stool microscopy were normal. Malaria and tuberculosis workup, filarial antigen, rK39 antigen and TORCH profile were negative. A contrast-enhanced computed tomography (CT) abdomen revealed hepatomegaly with heterogeneous enhancement and periportal low attenuating areas, likely representing periportal fibrosis (**Figure 1**). The clinical picture was that of febrile hepatosplenomegaly with severe anaemia and eosinophilia. The differentials included parasitic infestation, malignancy and chronic liver disease with drug induced liver injury. A liver biopsy was done to establish the diagnosis.

The liver biopsy (**Figures 2-4**) showed expanded portal tracts with portal and periportal fibrosis. The portal areas showed numerous confluent necrotising granulomas and peripheral eosinophilic and histiocytic response along with fibroblastic rimming. Within the granulomas, numerous spherical to ovoid structures were identified. They showed a double- enveloped wall with fine radial striations between the two layers. Some showed unipolar to bipolar mucous plugs. This distinct morphology confirmed to that of *C. hepatica* ova. No adult worms were seen. Additionally, an extensive foreign body giant cell response was identified. Eosinophilic microabscesses were noted in the hepatic parenchyma. A final diagnosis of granulomatous hepatitis due to *C. hepatica* was given.

Following the biopsy report, the patient's history was reviewed and it was found that the child's residence was near a granary infested by rats. A history of pica was given by the patient's mother. She was started on albendazole for 3 months along with oral steroids for 3 weeks. Haematinics and vitamin D supplementation were also started. A month following the diagnosis, the patient was afebrile witha decrease in liver and spleen size and normalization of the AEC.

Figure 1: CT abdomen showing hepatomegaly with periportal low attenuating areas, indicating periportal fibrosis.

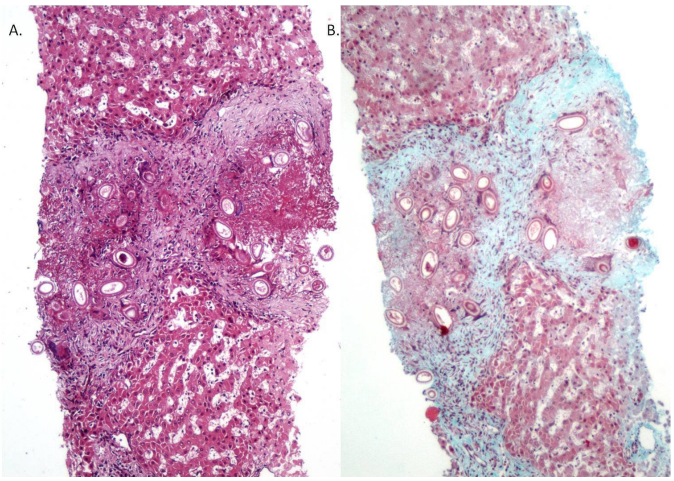

Figure 2: Liver biopsy core showing expanded portal tracts with central eosinophilic necrosis and surrounding fibroblastic response (Haematoxylin & Eosin, 40X and Masson's Trichrome, 40X).

Discussion

C. hepatica has a direct life cycle, requiring a single host; both adult worms and ova are present in the host liver.

These ova are unembryonated and thus, not infective. On death and decay of the organism, they are released into the soil, where they mature within a month to embryonated forms. True infection occurs when the embryonated ova are ingested by humans in contaminated food, water or soil. The larvae hatch in the small intestine and penetrate the portal vein to reach the liver where they form adult worms and copulate. The fertilised female deposits unembryonated eggs in the hepatic parenchyma; which subsequently become enclosed in granulomas. The adult worms die approximately forty to sixty days after infection[4]. The disintegrating worms release cytokines which induce an eosinophil-rich inflammatory and fibrotic response in the liver.

Spurious infection occurs when a scavenger predates upon theinfected host and unembryonated eggs reach its gut causing transient gastrointestinal symptoms. Over 78 cases of spurious infection (pseudocapillaria) have been reported in humans from South America and China[3]. Seventy four cases of true infection have been reported worldwide, only six of which are from India (5 from Maharashtra and 1 from Uttar Pradesh). Poor hygienic conditions and the presence of rodents increase the risk of infection. Sixty percent of cases reported are in children less than 8 years of age, the youngest being an 11 month male[3]. Frequent soil- hand- mouth contact explains the increased susceptibility in children.

The clinical manifestations are variable depending on the parasite load. A diagnosis is difficult to make due to the non-specific symptoms and radiology, non availability of immunologic tests for detection and absence of ova in stools in true infection[5]. Laboratory tests show leucocytosis, eosiniphilia and elevated liver enzymes. Definite diagnosis is by liver biopsy and identification of *C. hepatica* ova. The eggs of *C. hepatica* have to be differentiated from those of Schistosomiamansoni. The smaller size of *C. hepatica* ova, regular striations, birefringent bi-layered capsule and mucus plugs help clinch the diagnosis[5]. Schistosoma japoni cumova are of similar size as *C. hepatica* (60 X 30 µm); however. they possess lateral knobs and an acid fast shell. The eggs of Trichuris trichura (passed in stool) are ovoid and have bipolar plugs but lack a striated envelope.

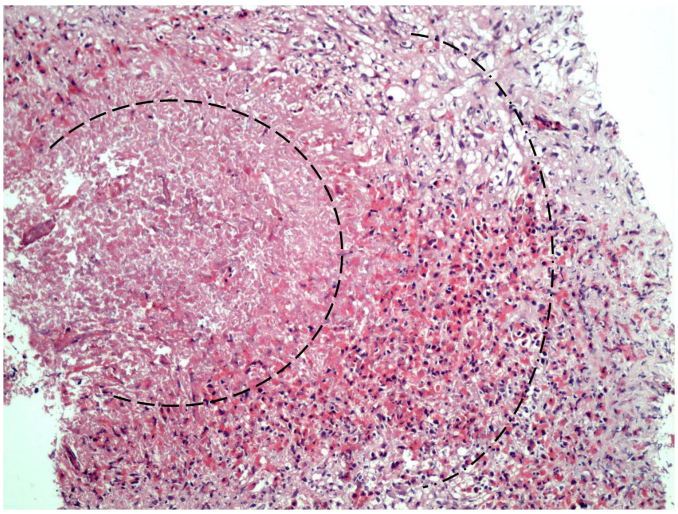

Figure 3: Confluent necrotising granuloma with palisading eosinophil rich response (H&E-100X).

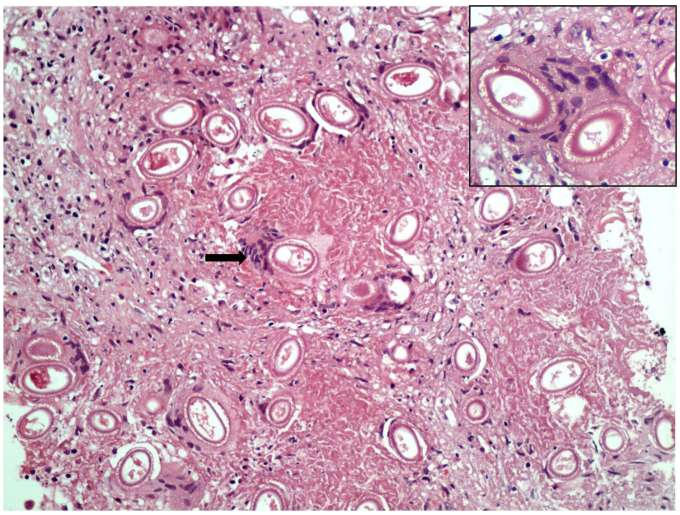

Figure 4: Numerous double layered ova of C-hepatica seen within a portal area with surrounding loose fibrosis (H&E, 200X) inset; Arrow Ova of C. hepatica being engulfed by foreign body giant cells (H&E, 400X).

Hepatic capillariasis is treated with benzimidazoles; steroids maybe given to reduce inflammation[3,5]. The prognosis depends on the severity of the infestation. Massive necrosis of the liver parenchyma and advanced fibrosis can lead to mortality. Therefore, a picture of tropical eosinophilia syndrome, especially in children should warrant suspicion for *C. hepatica*

infection. A detailed environmental history is vital. Since histopathology is the cornerstone for diagnosis, it is imperative for pathologists to be aware of this rare entity.

References

1. Moravec F. Proposal of a new systematic arrangement of nematodes of the Family Capillariidae. Folia Parasitologica. 1982; 29: 119-32.
2. Bancroft T.L. On the whip-worm of the rats liver. Journal and Proceedings of the Royal Society of New South Wales. 1893; 27: 86-90.
3. Fuehrer HP, Igel P, Auer H. Capillaria hepatica in man--an overview of hepatic capillariosis and spurious infections. Parasitol Res. 2011; 109: 969-79.
4. KA Wright. Observations on the life cycle of capillaria hepatica (Bancroft, 1893) with a description of the adult. Can J Zool. 1961; 39: 167-82.
5. Sawamura R, Fernandes MI, Peres LC, Galvão LC, Goldani HA, Jorge SM. Hepatic capillariasis in children: Report of 3 cases inBrazil. Am J Trop Med Hyg 1999;61:642-7.

Primary Isolated Retroperitoneal Hydatid Cyst: A Case Report

Satish Devakumar Murugesan[1]
Srinivasan Ulagendra Perumal[1]
Venkateswaran Rajeswaran Arcot[2]
Naganathbabu Obla[1]

[1]Department of Surgical Gastroenterology, [2]Department of Medical Gastroenterology, Madras Medical College, Chennai, India.

Corresponding Author: *Dr Satish Devakumar Murugesan*
Email: dr.satishdevakumar@gmail.com

Hydatid Disease (HD) is a serious public health problem in sheep and cattle raising countries like Australia, Africa, South America, Middle East and India. It is caused by the larval stage of Echinoccocus granulosus. It usually affects the liver (60-70%) and the lung (20-30%), but can develop anywhere in the body (5-10%) including the spleen, pancreas, kidney, peritoneum, retro-peritoneum, soft tissue, breast and central nervous system[1].

Retroperitoneal hydatid cysts are usually secondary to spontaneous/traumatic rupture of liver hydatid cysts or surgical inoculation of liver hydatid cysts[2]. Primary isolated retroperitoneal hydatid cyst (PIRHC) without liver and lung involvement is extremely rare. We report herein a case of primary retroperitoneal hydatid cyst without any other organ involvement.

Case Report

A 45-year-old woman was admitted in our hospital with oneyear history of pain in the right lower quadrant of the abdomen. Six months earlier, she had noticed a lump in the right lower quadrant of abdomen. There were no complaints of altered bowel habits, fever, vomiting, jaundice or gastrointestinal bleed. She had a normal appetite and no history of weight loss. Her vital signs were normal. Systemic examination was normal. Local examination revealed a 15x10 cm non-tender lump in the right iliac fossa, which did not fall forward in knee-elbow position. Per vaginal and per-rectal examinations were normal.

Blood investigations were within normal limits. Ultrasonography of the abdomen showed a 15x10 cm well-defined cystic lesion with thick sepations and multiple daughter cysts. The features were suggestive of a retroperitoneal hydatid cyst. Contrast enhanced Computerised Tomography (CECT) abdomen (**Figure 1**) showed a 15 x 9.5 cm large well defined, lobulated cystic lesion extending from the right sub-hepatic region to the right iliac fossa. The lesion had a multi-loculated appearance with numerous peripherally arranged daughter cysts. The lesion displaced the right kidney superiorly with alteration of the renal axis. The right hemi colonwas displaced anteriorly. The liver appeared normal. The findings were suggestive of a retroperitoneal hydatid cyst. Serological testing for hydatid disease (latex agglutination test) was negative. Based on clinical and imaging evidence, a provisional diagnosis of primary isolated retroperitoneal hydatid cyst was made and albendazole was started before surgery.