given and oral vancomycin was given after that for the next 5 days. Sigmoidoscopy was done and if lesions are present, the same cycle was repeated.[5,6] In our case, the patient required four such cycles and sigmoidoscopy after the fourth FMT showed complete resolution of the lesions with significant clinical improvement.

Conclusion

FMT is a good modality for the first attack of severe CDI not responding to standard lines of management. This case illustrates the importance of FMT in severe refractory C. difficile colitis.

References

1. Lee CH, Steiner T, Petrof EO, *et al*. Frozen vs fresh fecal microbiota transplantation and clinical resolution of diarrhea in patients with recurrent Clostridium difficile infection: a randomized clinical trial. JAMA 2016;315:142.
2. Mullish BH, Quraishi MN, Segal JP, *et al*. The use of faecal microbiota transplant as treatment for recurrent or refractory Clostridium difficile infection and other potential indications: joint British Society of Gastroenterology (BSG) and Healthcare Infection Society (HIS) guidelines. Gut 2018; 67:1920.
3. Bakken JS, Borody T, Brandt LJ, *et al*. Treating Clostridium difficile infection with fecal microbiota transplantation. Clin Gastroenterol Hepatol. 2011; 9:1044–1049.
4. Brandt LJ, Borody TJ, Campbell J.Endoscopic fecal microbiota transplantation: "first-line" treatment for severe Clostridium difficile infection? J Clin Gastroenterol 2011; 45: 655–7.
5. Fischer M, Sipe BW, Rogers NA, Cook GK, Robb BW, Vuppalanchi R, *et al*: Faecal microbiota transplantation plus selected use of vancomycin for severe-complicated Clostridium difficileinfection: description of a protocol with high success rate. Aliment PharmacolTher 2015; 42: 470–6.
6. Cammarota G, Masucci L, Ianiro G, *et al*. Randomised clinical trial: faecalmicrobiota transplantation bycolonoscopy vs. vancomycin for thetreatment of recurrent Clostridiumdifficile infection. Aliment PharmacolTher 2015; 41: 835-43.

Isolated Pancreatic Tuberculosis Presented as SOL

Sunil Raviraj Kothakota[1]
Madhu Sasidharan[2]
Harish Kareem[2]
Ajith K Nair[2]
Shabeerali TU[3]
Vidya C[4]

[1]Senior Resident, [2]Consultant Gastroenterology, [3]Consultant Surgical Gastroenterology, [4]Pathologist, Kerala Institute of Medical Sciences (KIMS), Trivandrum. Kerala. India.

Corresponding Author: *Dr Sunil Raviraj Kothakota*
Email: ksrdnb@gmail.com

Abdominal TB has been reported in 11-16% cases with extra pulmonary cases[1]. Isolated pancreatic involvement is rare in both immunocompetent and immunocompromised conditions[2]. Here we report a case of pancreatic SOL (space occupying lesion), suspected as solid cystic lesion of pancreas on imaging, which was finally diagnosed as pancreatic tuberculosis.

Case Report

We report a case of 24-year-old female with no known co-morbidities who was evaluated for unintentional weight loss. She lost 12 kg weight in 1-year duration and had complaints of easy fatigability and occasional pain abdomen. She never had fever, altered bowel habits, cough or chest pain. On evaluation her hematological profile showed low haemoglobin (9.6 gram%, MCV 83fl) and normal leucocyte and platelet counts. Liver and renal profiles were within normal limits. Erythrocyte sedimentation rate was on higher side (60 mm in 1st hr). In view of abdomen pain, ultrasound abdomen was performed and found to have heterogenous hypoechoic lesion superior to and abutting body of pancreas along with evidence of cholelithiasis. Markers for malignancy were negative (CEA, CA 19-9). Computerized tomography (CT) abdomen showed well-defined cystic lesion

(3.37 × 1.98 cm) with homogenous contents arising from superior margin of pancreas and irregular wall thickening / soft tissue component in posterio superior aspect of lesion with no inflammatory fat stranding or calcification suggestive of pancreatic cystic neoplasm (**Figure 1**). She underwent endoscopic ultrasoundguided fine needle biopsy (EUS-FNB), but tissue examination was inconclusive despite presence of adequate tissue. Repeated EUS-FNB also did not give diagnosis. Later diagnostic laparoscopy was performed. Intraoperatively supra-pancreatic cyst of 3.5 × 3 cm lesion noted. On opening of the cyst wall, whitish cheese caseous material noted and about 25 ml of material aspirated. Cyst wall showed necrosis. Cystic material was biopsied. Tissue was sent for histopathology examination (HPE), acid fast bacilli (AFB) culture and MTB Gene Xpert. Pancreatic cyst wall tissue HPE revealed presence of chronic inflammatory cells, granulomas with epitheloid cells (**Figure 3**). MTB Gene Xpert of cyst material was found positive. With these findings she was diagnosed as isolated pancreatic tuberculosis started on 4 drug anti tubercular regimen. She improved clinically well and started gaining weight.

Discussion

Primary pancreatic tuberculosis is an unusual manifestation and its almost always a histological surprise. In the absence of other manifestations of Koch's it is very difficult to suspect isolated TB infection in pancreatic lesions. It may mimic pancreatic malignancy, other cystic lesions of pancreas or autoimmune pancreatitis. Involvement of pancreas by mycobacterium can be due to lympho-hematogenous spread or from adjacent organs[3]. There is no literature regarding the typical presentation of pancreatic TB, due to its rarity. Few authors denote that it may present as pain abdomen, weight loss or fever episodes. Radiological features are non-specific, may masquerade as neoplastic lesions, which may sometimes warrant major surgical intervention on suspicion of malignancy[4]. Pombo *et al*. studied imaging features of 6 patients with pancreatic TB and found three patterns of lesions i.e. mass forming, diffuse and small nodular type[5]. Among all mass forming type was most common. Our patient also presented with loss of weight and fatigue and found to have mass forming lesion in body of pancreas. EUS-FNB is a safe and promising method

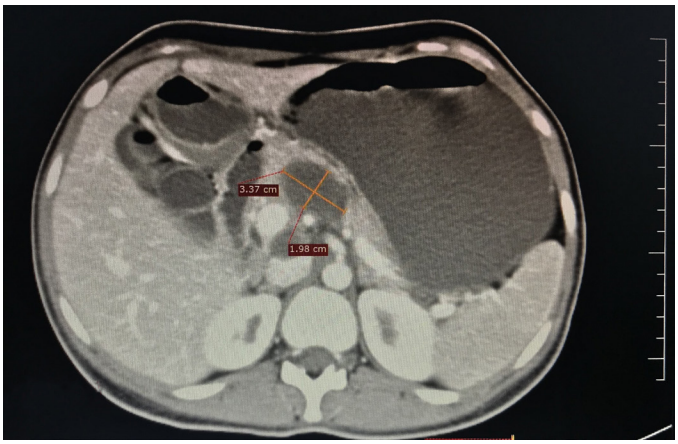

Figure 1: Computerized tomography (CT) abdomen showed well defined cystic lesion (337 x 198 cm) with homogenous contents suggestive of pancreatic cystic neoplasm.

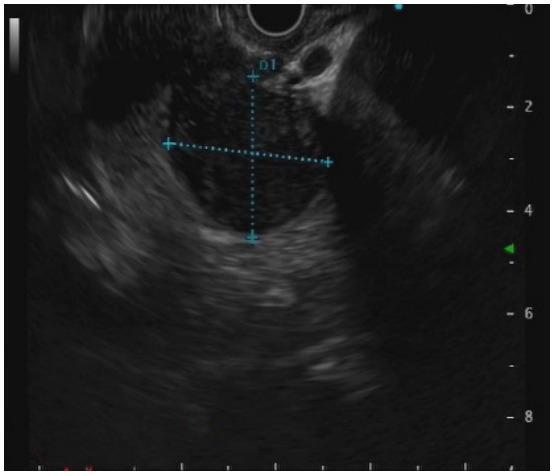

Figure 2: EUS-FNB of pancreatic SOL.

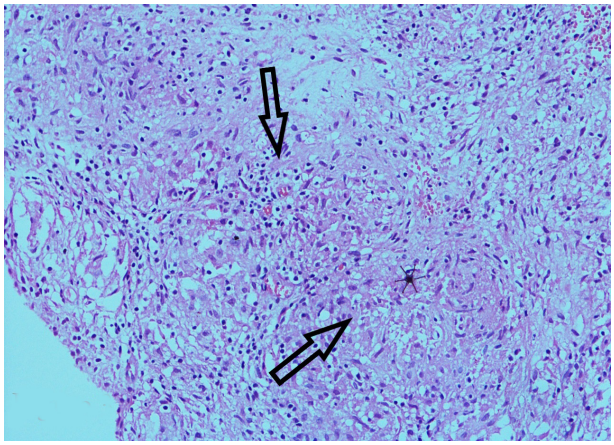

Figure 3: Pancreatic cyst wall tissue histopathology (HE stain) showed presence of chronic inflammatory cells, granulomas with epitheloid cells.

for the diagnosis of pancreatic/peripancreatic TB. In a retrospective analysis done in Korean study by Song *et al*, it was found that EUS-FNB gave diagnosis in 76.2% patients (16 out of 21)[6]. However, in our patient EUS-FNB examination was inconclusive. Laparoscopy will help whenever there is diagnostic dilemma. Along with tissue sampling, other tissue involvement can be visualized on laparoscopy. Along with tissue sampling, other tissue involvement can be visualized on laparoscopy. Presence of caseating granulomas on histopathology, demonstration of TB bacilli on ZN stain, culture or GeneXpert positivity are diagnostic features. Abdominal tuberculosis responds well to anti tubercular treatment unless it is a drug resistant scenario. It is recommended to give 6 months course of anti-tubercular treatment (ATT) for abdominal TB[7]. Our patient symptomatically responded well to ATT and she is on follow up now.

Conclusion

Pancreatic tuberculosis is very rare, but whenever there is diagnostic dilemma in a pancreatic SOL, tuberculosis should be considered before planning surgery with the suspicion for neoplastic lesion.

References

1. Khan R, Abid S, Jafri W, *et al*. Diagnostic dilemma of abdominal tuberculosis in non-HIV patients: an ongoing challenge for physicians. World J Gastroenterol 2006;12:6371-5.
2. Elizondo ME, Arratibel JA, Compton CC, Warshaw AL. Tuberculosis of pancreas. Surg 2001;129 :114-6.
3. Singh DK1, Haider A, Tatke M, Kumar P, Mishra PK. Primary pancreatic tuberculosis masquerading as a pancreatic tumor leading to Whipple's pancreaticoduodenectomy. A case report and review of the literature. JOP. 2009;10(4):451-6.
4. Pombo F, DíazCandamio MJ, Rodriguez E, Pombo S. Pancreatic tuberculosis: CT findings. Abdom Imaging 1998;23:394-397.
5. Pombo F, DíazCandamio MJ, Rodriguez E, Pombo S. Pancreatic tuberculosis: CT findings. Abdom Imaging 1998;23:394-7.
6. Song TJ, Lee SS, Park DH, Lee TY, Lee SO, Seo DW *et al*. Yield of EUS-guided FNA on the diagnosis of pancreatic/peripancreatic tuberculosis. GastrointestEndosc. 2009;69:484-91.
7. Index TB guidelines for extra pulmonary tuberculosis in India. Chapter 15. Page 63. https://tbcindia.gov.in/showfile.php?lid=3245. (browsing done on 05-08-2018).

Gastrointestinal Stromal Tumor of the Anal Canal: An Extreme rarity

Monika Gupta
Namita Bhutani
Sandeep Yadav
Lovekesh Monga
Renuka Verma
Rajeev Sen

Department of Pathology, PGIMS Rohtak, Haryana, India.

Corresponding Author: *Dr Namita Bhutani*
Email: namitabhutani89@gmail.com

Gastrointestinal stromal tumours (GIST) are rare entities with malignant potential. They accounts for 1% of all primary gastrointestinal (GI)tumours. They are the most common mesenchymal neoplasms of the GI tract. As reported by Nilsson *et al*, epidemiological data is virtually non-existent regarding the true incidence and prevalence of GIST[1]. This is due to the previous lack of well-defined pathologic criteria for GIST, their varying nomenclature over the past few decades, and the finding that nearly 60% of all GIST have been diagnosed as benign tumours or tumours of uncertain malignant potential due to which they are not reported to national cancer registries[1]. We present the case of an anal GISTtreated by local excision so as to discuss the diagnosis, surgical treatment and adjuvant therapy of these rare lesions.

Case Report

A 75-year-old female presented to the surgery outpatient department with complaints of irregular bowel habits, constipation, dark coloured stools mixed with the blood and pain during defecation for 6 months. The pain was non-radiating, dull aching, persistent and increased with atraining for stool. The blood in the patient's stool was frank red and came as drops after passage of stool. There was no tenesmus, no dizziness or weakness There was no significant relief in symptoms with medication. The