A Rare Cause of Abdominal Emergency In SLE

K Sriharsha
Venkatesh Munikrishnan
Sudeepta Kumar Swain
Darshan Kumar Kantibhai Patel
Azaz Ahmed

Department of Surgical Gastroenterology Apollo Main Hospital, Chennai, India.

Corresponding Author: *Dr K Sriharsha*
Email: kolluharsha@gmail.com

SLE is an autoimmune disease characterized by the presence of a plethora of autoantibodies and immune complex formation. SLE can affect virtually every system in the body. Gastrointestinal symptoms are not uncommon in SLE patients and are mainly due to lupus enteritis drug reactions and infections due to steroids.[1] Intussusception is the telescoping of the proximal segment of the gut into the distal segment. It is more common in children, but it can also be seen in adults. Underlying pathologies can be numerous.

Case Report

Our patient is a 34yr old female with no known comorbidities, who underwent a right tubo-ovarian mass excision for a tubal ectopic. She had an uneventful post-operative recovery and was discharged on POD-1. She started having intermittent dull aching lower abdominal pain from POD -2. On POD-8, she developed a low-grade fever, polyarthralgia, bilateral lower limb swelling, and multiple erythematous patches (**Figure 1,2**). On evaluation, she was diagnosed with SLE (ANA, ds DNA positive) and was started on steroids, and her skin patches regressed. After one week, she was again admitted to the ER with severe abdominal pain and nausea. On examination, she has diffuse abdominal tenderness, more so in epigastrium. Investigations showed anemia and neutrophilic leukocytosis. CECT abdomen showed

Figure 1: Multiple erythematous patches .

Figure 2: Non erosive arthritis.

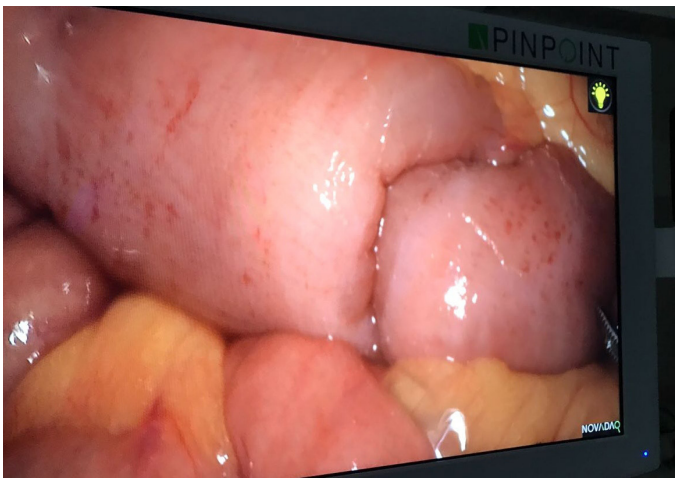

Figure 3: Diagnostic lap intra operative image.

multiple areas of jejunal and ileal wall thickness, minimal ascites, and few enlarged mesenteric nodes.

She was managed conservatively with NBM and IV fluids, but she failed to improve. She was planned for a diagnostic laparoscopy because of her persistent symptoms. Diagnostic laparoscopy revealed an area of jejunal intussusception (**Figure 3**). She underwent resection anastomosis, and the resected specimen showed a submucosal hemorrhage, which was acting as a lead point for intussusception (**Figure 4**).

Discussion

SLE is an autoimmune disease with varied presentations affecting almost every system of the body. SLE related vasculitis is inflammation of the vessel wall; the presentation can be varied due to its capacity to affect vessels of varied sizes (arteries, veins, and capillaries) and sites (skin or viscera) with prognosis ranging from mild to life-threatening. Intestinal involvement in SLE is generally either lupus enteritis or drug-related, but gastrointestinal vasculitis can cause thrombosis and can lead to life-threatening ischemia, infarction, and perforation requiring emergent surgical interventions.[2]

Small bowel intussusception in adults is not uncommon, but unlike in children, adults have an underlying pathology in 80-90% of cases. Renzulli and Candinas stated that 60% of adult small bowel intussusceptions are due to benign causes, 30% are due to malignancy, and 10% are idiopathic. The most common benign causes include fibrous polyps, lipomas, hemangiomas lymphadenitis, and diverticulae.

Rarely intussusception is caused by spontaneous hematomas, mainly due to anticoagulant therapy or due to drugs.[3] In our case, hematoma, as a lead point, occurred due to SLE induced vasculitis, which is an infrequent presentation.

These patients generally present with intestinal obstruction or recurrent episodes of abdominal pain. Diagnosis is generally obtained by imaging, especially CT scan, which shows the site of intussusception, proximal bowel dilatation, and target sign.[4] In cases with a diagnostic dilemma, a diagnostic laparoscopy helps in identifying the pathology.

Figure 4: Resected specimen showing hematoma.

Treatment includes an initial trial of conservative therapy or surgical resection in those who fail to respond to conservative measures.

Conclusion

Small bowel intussusception due to vasculitis induced spontaneous intramural or submucosal hemorrhage is a rare presentation of SLE associated vasculitis. A high index of suspicion and proper imaging helps in diagnosing and treating this rare scenario. We conclude by saying that spontaneous vasculitis induced hemorrhage should be born in mind in those patients with SLE presenting with abdominal pain.

References

1. Malaviya AN, Sharma A, Agarwal D, Kapoor S, Singh S, Rawat R. Acute abdomen in SLE. International journal of rheumatic diseases. 2011 Feb 1:14(1):98-104.
2. Paskauskas S, Pavalkis D. Adult intussusception. In Current Concepts in Colonic Disorders 2012. InTech.
3. Peterson CM, Menias CO, Balfe DM, Freeman BA. Adult intussusception due to cocaine-induced bowel wall hematoma: a case study. Emergency radiology. 2006 May 1;12(4):177-9.
4. Choi SH, Han JK, Kim SH, Lee JM, Lee KH, Kim YJ, An SK, Choi BI. Intussusception in adults: from stomach to rectum. American Journal of Roentgenology. 2004 Sep;183(3):691-8.