in their relative intra-abdominal positions after meals (as hypothesized in ISK) may contribute.[1-5] The presence of adhesions, around which loops of small bowel might twist, has also been hypothesized[5] possibly, altered gut mobility[6] after LC in our patient may have in some way contributed to the knotting of the ileum upon itself, but a definite etiology remains obscure.

As there are no pathognomic etiological, clinical or radiological features, ileo-ileal knotting is usually not diagnosed pre-operatively;[1,2,5] these patients present with symptoms and signs of intestinal obstruction, and as is the case when strangulation occurs, progress rapidly towards septicemia and multi-organ failure due to intestinal occlusion, ischemia, and gangrene.[1-3,5] The condition is often diagnosed intra-operatively, once the knot is visualized. If the bowel is viable and strangulation has not yet supervened, untying the knot is recommended[1-3,5] since recurrence is uncommon.[1] However, this carries a risk of perforation, especially if multiple attempts are made.[1-3,5] If the bowel unviable, as in our patient, en bloc resection of the segment after controlled decompression of its contents followed by exteriorization or anastomosis, based on the surgeon's experience is preferred.[1-5]

References

1. Uday S, Venkata PKC, Bhargav P, Kumar S. Ileo-ileal knot causing small bowel gangrene: an unusual presentation. Int J Case Rep Imag 2012;3:28-30. doi: 10.5348/ ijcri-2012-05-121-CR-6
2. Taniguchi K, Iida R, Watanabe T, Nitta M, Tomioka M, Uchiyama K, Takasu A. Ileo-ileal knot: a rare case of acute strangulated intestinal obstruction. Nagoya J Med Sci. 2017;79:109-113. doi: 10.18999/nagjms.79.1.109
3. Abebe E, Asmare B, Addise A. Ileo-ileal knotting as an uncommon cause of acute intestinal obstruction. J Surg Case Rep. 2015; 8: 1 - 2.doi: 10.1093/jscr/rjv102
4. Kalachelvan L, Perumal SU, Ross K, Subramanian B. Ileo-Ileal Knot Causing Intestinal Obstruction – A Case Report. OSR-JDMS 2016; 15: 26 – 9. DOI: 10.9790/0853-150732629
5. Gopivallabh MM, Jaganmaya K, Hanumanthaiah KS, Babannavar P, Crithic V. Ileoileal Knot as a Content of Obstructed Hernia: What Are the Odds? Iran J Med Sci. 2016; 41:238–240
6. Madacsy L, Dubravcsik Z, Szepes A (2015) Postcholecystectomy Syndrome: From Pathophysiology to Differential Diagnosis - A Critical Review. PancreatDisordTher 5: 162. doi:10.4172/2165-7092.1000162

Disseminated Histoplasmosis Presenting as Lower Gastrointestinal Bleeding in an Immunocompetent Individual: A case report and review of the literature

Subhashish Das[1]
Atul Kakar[2]
Sabina Langer[3]
Samiran Nundy[1]

[1]Department of Surgical Gastroenterology and Liver Transplantation, [2]Department of Medicine, [3]Department of Hematology, Sir Ganga Ram Hospital, New Delhi, India.

Corresponding Author: *Dr Subhashish Das*
Email: subhamsubham1@yahoo.co.in

Histoplasmosis is an important systemic fungal infection caused by a dimorphic fungus, Histoplasma capsulatum. In India, the disease has been reported from several parts of the country - most cases being from eastern India, considered to be endemic for the disease. The causative fungus is present in the soil, acquired through inhalation, and has three types of manifestations - acute primary, chronic cavitary, and progressive disseminated histoplasmosis. Among the forms of histoplasmosis, Disseminated histoplasmosis (DH) is the rarest and generally found in immune-compromised individuals. It can manifest as varying symptoms because of the involvement of various organ systems. Here we present an immunocompetentpatient with disseminated histoplasmosis who presented withlowergastrointestinal(GI) bleeding.

Case Report

A 48 year-old male from Delhi, without any previous co-morbidities, presented to us with a 15 day history of high-

grade intermittent fever with loss of weight and appetite. He had no history of unprotected sexual exposure, diabetes mellitus, or tuberculosis. On physical examination, he had a Body Mass Index of 17 kg/m^2, pallor and had an ulcer over the hard palate. Investigations showed pancytopenia (Hb - 7.9 gm/dL, TLC - 2300 cells/mm^3, Platelet count - 55,000/mm^3). Serology for HIV- 1 and 2 was negative. Abdominal ultrasonographyand CECT of the abdomen revealed hepato-splenomegalywith minimal free fluid in the pelvis.

Bone marrow biopsy showed normal cellular marrow and phagocytes engulfing the yeast cells (**Figure 1**). Bone marrow culture in Saboraud's Dextrose Agar and Brain Heart Infusion Agar grew colonies of Histoplasma capsulatum.

During his hospital stay, he developed bleeding per rectum containing dark blood with clots, for two days. UGI endoscopy was normal, and colonoscopy revealed caecal erosions, a biopsy of which showed features of histoplasmosis (**Figure 2**).

He was treated with intravenous Amphotericin B(AMB) 100 mg twice daily, and the dose was gradually escalated. After 3 days of starting treatment the fever episodes and per-rectal bleeding subsided. After seven days of anti-fungal course, he was discharged in a stable condition and advised home-based IV AMB, for a total dose of 3 gm.

On follow up, his lab parameters improved substantially, and USG of the abdomen also revealed a decrease in the size of his spleen. However, after four weeks of discharge, he noticed cutaneous nodules (**Figure 3**) starting on the ventral aspect of his trunk that spread rapidly to involve the dorsum as well as the upper limbs. However, there were no associated symptoms except occasional malaise. Biopsy from the cutaneous nodules revealed cutaneous histoplasmosis (**Figure 4**). Finally, he was started on tablet Itraconazole 200 mg twice daily and is now on regular follow up with the resolution of the cutaneous nodules (**Figure 5**).

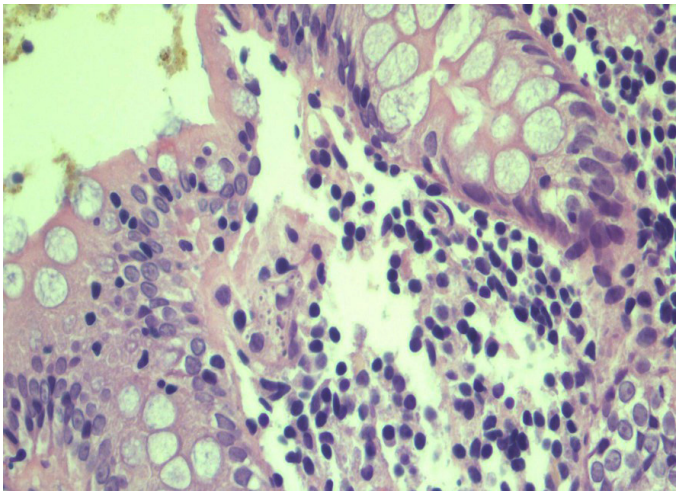

Figure 2: Caecal biopsy - within the lamina propria, both extracellulary and intracellularly within the macrophage, there are small oval spores compatible with Histoplasmosis, stain positively with special stain (PAS).

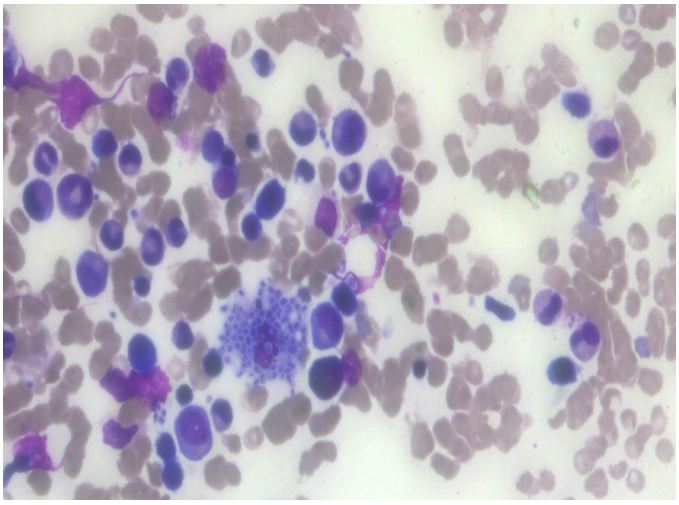

Figure 1: Bone marrow biopsy - phagocytes containing Histoplasma.

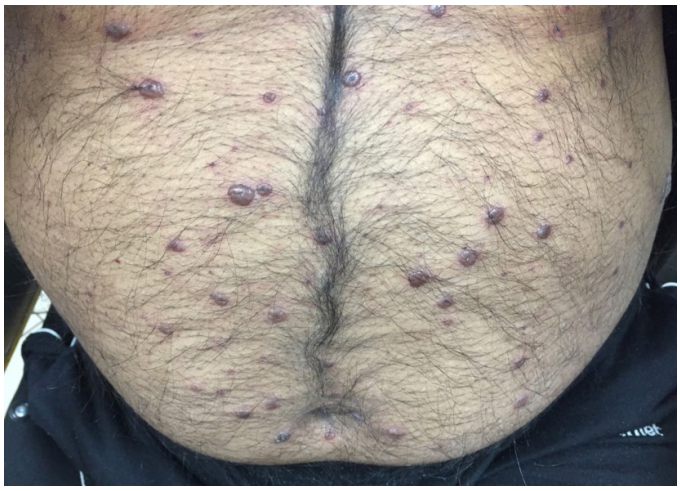

Figure 3: Cutaneous nodules: cutaneous papular lesions with centrally umbilicated, looks like Molluscum.

Discussion

Inhalation of either fungal conidia or mycelial fragments is the primary mode of acquisition of histoplasmosis. Once inhaled, these fungal elements transform into yeast forms and may disseminate systemically. The clinical manifestations of histoplasmosis often appear after prolonged exposure to large inocula. The initial pulmonary infection may disseminate systemically with hematogenous spread and produce extra-pulmonary manifestations, and spread to the regional lymph nodes through the lymphatics. Primary pulmonary histoplasmosis is usually asymptomatic (approximately 90%) or presents with subclinical disease. Symptomatic hosts with primary pulmonary histoplasmosis often present with nonspecific symptoms of fever, chest pain, and cough, which are self-limited. Systemic spread usually occurs in patients with impaired cellular immunity, including patients with hemato-lymphoid malignancies, solid organ transplants, and those exposed to immuno

suppressive agents. The development of progressive DH indicates impaired cell-mediated immune responses. Patients who are immunosuppressed and thus unable to develop effective cell-mediated immunity against the organism, are likely to manifest symptomatic disease during the period of acute dissemination. It may lead to the involvement of the central nervous system, the reticuloendothelial system(RES), including the liver, spleen, lymph nodes, bone marrow, and rarely, the mucocutaneous tissues. Progressive disseminated histoplasmosis occurs in 1 per 2000 cases in adults who are immunocompetent[1]. Histoplasmosis capsulatum is endemic to Ohio, Missouri, and Mississippi River valleys in the United States, as well as some river valleys in Central America[2]. In India, histoplasmosis is found predominantly along the Gangetic plains, namely West Bengal and Uttar Pradesh[2].

Progressive disseminated histoplasmosis is rare in immunocompetent adult hosts. The size of the inoculum plays an important role such that immunocompetent adults exposed to a low quantity of inoculum are usually asymptomatic. However, the inhalation of a large inoculum can cause diffuse pulmonary symptoms and may have a protracted course. Chronic progressive DH is a slowly progressive infection due to Histoplasma capsulatum that occurs mostly in older adults who are not overtly immunosuppressed[3]. These patients have no obvious immunosuppression, but their macrophages cannot effectively kill H. capsulatum[3].

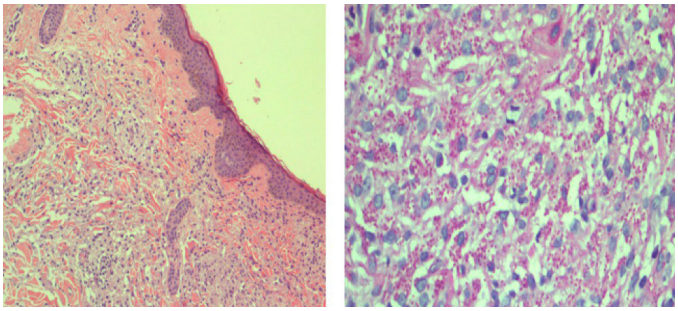

Figure 4: Skin biopsy (left): infiltration of dermis by sheets of histiocytes, (right) most of them were loaded with numerous fungal profiles with clear halo around them suggestive of Histoplasmosis.

Figure 5: Resolution of cutaneous nodules after treatment.

The symptoms of DH include fever, malaise, anorexia, and weight loss. Physical examination often shows hepatosplenomegaly, lymphadenopathy, pallor, and petechiae due to RES involvement. In some patients, mucous membrane ulcerations, skin ulcers, nodules, or molluscum-like papules may be present[3]. Among the forms of histoplasmosis reported from India, DH is the rarest.

Numerous case series have published histoplasmosis from all over India, the most extensive series being from Delhi, a compilation of 37 patients from all over India4. Since clinical and laboratory features have considerable overlap, it is important to consider fungal infections while dealing with a disseminated granulomatous infection, even in immunocompetent hosts.

We present a case of disseminated histoplasmosis in an immunocompetent individual presenting with fever and a palatal ulcer who later developed lower GI bleeding and cutaneous nodules. Frequently, in cases of disseminated infection, oral lesions appear as the initial clinical manifestation. The palate, gingiva, and oropharynx are the most frequent sites of oral histoplasmosis. Oral lesions can vary from ulcers, erythematous or vegetative nodules, to wart-like growths. Many reports show the development of ulcerating, indurated, and painful ulcers.

Isolated intestinal histoplasmosis is uncommon. The majority of intestinal histoplasmosis cases occur with disseminated disease and hence are more likely to be encountered in immunodeficient patients. GI involvement occurs in 70%-90% of cases of DH5, manifesting as abdominal pain, diarrhea, anorexia, nausea, bilious vomiting, constipation, tenesmus, and abdominal tenderness[5]. There are also reports of GI complications such as bleeding, bowel obstruction, perforation, and even protein loss due to enteropathy. Healthcare providers may miss the diagnosis as GI endoscopic examinations are not offered sometimes due to a lack of related symptoms. Our case highlights the occurrence of disseminated histoplasmosis in an immunocompetent patient with caecal erosions found on colonoscopy and diagnosis confirmed by biopsy and fungal culture.

Progressive DH is treated beginning with lipid formulation amphotericin B (3-5 mg/ kg/d) or amphotericin B (0.7-1.0 mg/kg/d for 1-2 weeks), followed by Itraconazole (200 mg twice daily for 8-12 months) with a near complete resolution in most cases. However, failure to diagnose or treat at an appropriate time is uniformly fatal, especially in the disseminated form.

Conclusion

Disseminated histoplasmosis is not uncommon in India with high prevalence areas along the Gangetic plains. Our case describes the occurrence of progressive disseminated histoplasmosis in an immunocompetent individual, from a non-endemic area, with predominant gastrointestinal involvement and pancytopenia. He initially responded to treatment with Amphotericin B, but later disease recurred with cutaneous nodules, which responded further to treatment with Itraconazole.

References

1. Kauffman CA. Histoplasmosis: a clinical and laboratory update. Clin Microbiol Rev. 2007; 20:115-32.
2. Randhawa HS, Khan ZU. Histoplasmosis in India: current status. Indian J Chest Allied Sci. 1994; 193-213.
3. Goodwin RA, Shapiro JL, Thurman GH, Thurman SS, Des Prez RM. Disseminated histoplasmosis: Clinical and pathological correlations. Medicine (Baltimore) 1980; 59:1–33.
4. Randhawa HS, Khan ZU. Histoplasmosis in India: Current Status. Indian J Chest Dis Allied Sci. 1994; 36:193–213.
5. Kahi CJ, Wheat LJ, Allen SD, Sarosi GA. Gastrointestinalhistoplasmosis. Am J Gastroenterol. 2005; 100:220–31.