

- and literature review. *Pediatric Surgery International*. 2006;22(4):387-389
12. Khmou M, Znati K, et al. Synchronous adenomyomas of the ileum in an adult- an exceptional cause of intussusception. *Clinical Case Report*. 2015;3(7):578-581
 13. Kim CJ, Choe GY, Chi JG. Foregut choristoma of the ileum (adenomyoma) - a case report. *Pediatric Pathology*. 1990;10(5):799-805
 14. Kwon TH, Park DH, et al. Ampullary adenomyoma presenting as a case of recurrent pancreatitis. *World J Gastroenterology*. 2007;13(2):2892-2894
 15. Lamki N, Woo CL, Watson AB, Kim HS. Adenomyomatous hamartoma causing ileoileal intussusception in a young child. *Clinical Imaging*. 1993;17(3):183-185
 16. Lee JS, Kim HS, Jung JJ, Kim JB. Adenomyoma of the small intestine in an adult: a rare case of intussusception. *Journal of Gastroenterology*. 2002;37(7):556-559
 17. Lo Bella Gemma G, Coradino R, Cavuoto F, Motto M. Myoepithelial jejunal hamartoma causing small bowel intussusception and volvulus. *Radiol Med*. 2003;105(3):246-249
 18. Mouravas V, Koutsoumis G, et al. Adenomyoma of the small intestine in children: a rare cause of intussusception: a case report. *Turkish Journal of Pediatrics*. 2003;45(4):345-347
 19. Nuño-Guzmán CM, Arróniz-Jáuregui J, et al. Adult intussusception secondary to an ileum hamartoma. *World J. Gastrointest. Oncol*. 2011;3(6):103.
 20. Park HS, Lee SO, et al. Adenomyoma of the small intestine: a report of two cases and review of the literature. 2003;53(2):111-114
 21. Qing X, Petrie BA, Bulson V, French S. Adenomyoma of the jejunum. *Experimental and Molecular Pathology*. 2009;86:127-130
 22. Rafiullah, Tanimu S. Adenomyomatous hyperplasia of the ampulla of Vater presenting as acute pancreatitis. *BMJ Case Report*. 2014.
 23. Rosenmann E, Maayan C, Lernau O. Leiomyomatous hamartosis with congenital jejunoileal atresia. *Israel Journal of Medical Sciences*. 1980;16(11):775-779
 24. Schwartz SI, Radwin HM. Myoepithelial hamartoma of the ileum causing intussusception. *AMA Archives of Surgery*. 1958;77(1):102-104
 25. Serour F, Gorenstein A, Lipnitzky V, Zaidel L. Adenomyoma of the small bowel: a rare cause of intussusception in childhood. 1994;18(2):247-249
 26. Takahashi Y, Fukusato T. Adenomyoma of the small intestine. *World J Gastrointest Pathophysiology*. 2011;2(6):88-92
 27. Takeda M, Shoji T, et al. Adenomyoma of the ileum leading to intussusception. *Case Rep Gastroenterol*. 2011;5(3):602-609
 28. Tanaka N, Seya T, et al. Myoepithelial hamartoma of the small bowel: report of a case. *Surg Today*. 1996;26(12):1010-1013
 29. Tomibayashi A, Sasaki S, et al. Adenomyoma of the small intestine in an adult: report of a case. *Surgery Today*. 2011;41(8):1101-1105
 30. Ueyama N, Kuwashima S, et al. Ileal adenomyoma accompanied by primary peritonitis: report of a case. *Surgery Today*. 2001;31(9):826-829
 31. Van Helden SH, Jutten G, Van Hoey H, Dierick AM. Jejunal hamartoma as a rare cause of gastrointestinal haemorrhage. *Histopathology*. 1998;32(6):574-575
 32. Yamagami T, Tokiwa K, Iwai N. Myoepithelial hamartoma of the ileum causing intussusception in an infant. *Pediatric Surg Int*. 1997;12(2/3):206-207
 33. Yao JL, Zhou H, et al. Adenomyoma arising in a Meckel diverticulum: case report and review of the literature. *Pediatric Dev. Pathol*. 2000;3(5):497-500
 34. Yu HC, Lo GH, et al. Adenomyoma of the jejunum - a rare cause of gastrointestinal bleeding. *J Chin Med Assoc*. 2008;71(2):96-99.

Dengue Transmission from Donor to Recipient After Living Donor Liver Transplant

Organ transplantation has been associated with a small but worrying risk of transmission of disease from donor to recipient. Initially reported for viral and bacterial infections following renal transplants¹, similar reports are now mushrooming world over following liver transplantation.² Whereas the common culprits, namely HIV, HBV, HCV, etc have been covered by screening

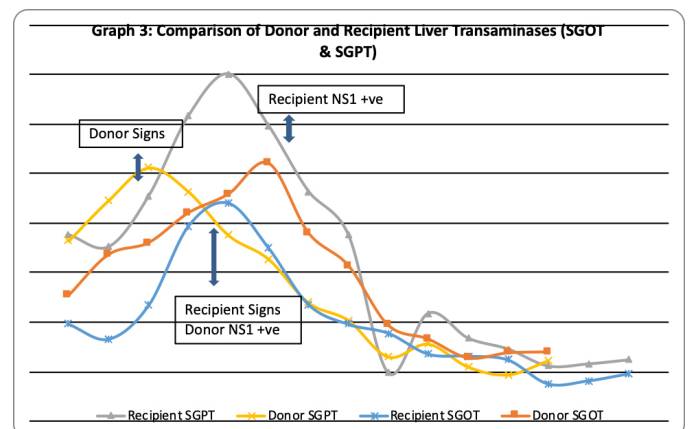
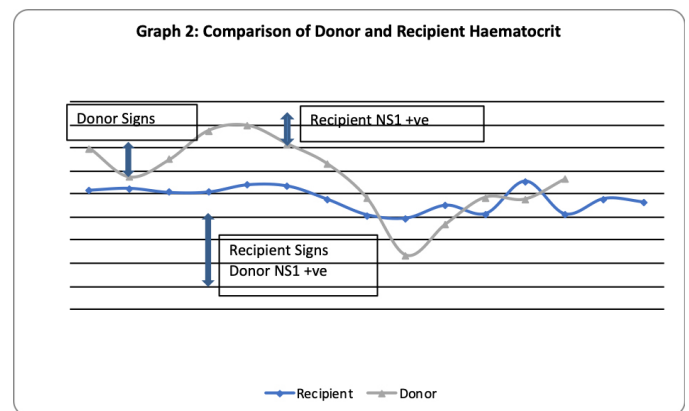
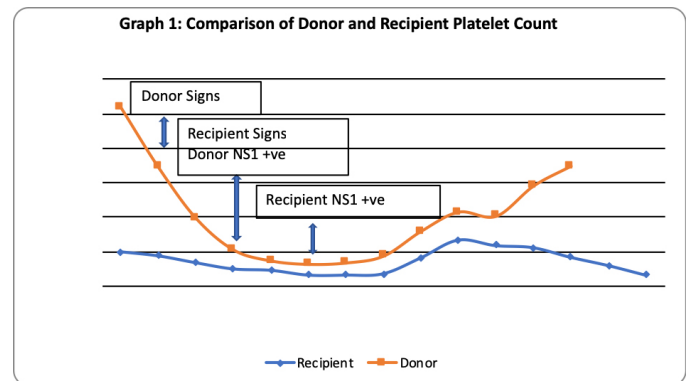
protocols in the transplant evaluation, certain endemic infections are increasingly being reported to be transmitted via this route and maybe an unsuspected risk in specific geographical areas. Donor-derived infections pose an avoidable source of mortality and morbidity for the immune suppressed recipient. We present an interesting case of donor to recipient transmission of dengue virus following living donor liver transplant, with the donor developing hemorrhagic fever, and recipient having acute febrile illness. We also aim to elucidate the need for expansion of pre-transplant evaluation to accommodate screening for such endemic illness in future.

Case Report

The case involves a 64 year old male diagnosed with non-alcoholic steato-hepatitis (NASH) related cirrhosis with hepatocellular carcinoma (HCC), within Milan criteria prepped for transplant. He underwent right lobe living donor liver transplantation (LDLT), the donor being his healthy 28 year old son. All pre-operative factors for recipient and donor were optimized prior to transplant. Routine recipient work up included testing for HIV, HBV, HCV, CMV and VZV; all these tested negative. Pan cultures were also found negative. The donor on the other hand was tested for HIV, HBV, HCV and CMV; all of which were deemed negative. Neither donor nor recipient had any episode of fever within two weeks of scheduled transplant date. The donor was detected to have the rare Bombay blood group type.

Intra-operatively, a right lobe with subtotal middle hepatic vein (MHV) graft was harvested from the donor. With favorable vascular and biliary anatomy, the donor operation was uneventful, with no transfusion requirements in the immediate peri-operative period. In the recipient procedure, cold and warm ischemia times were restricted to 61 and 52 minutes respectively, and total procedure was completed within nine hours and five minutes. An acceptable graft-recipient weight ratio (GRWR) of 0.86 was obtained. Intra-operative blood product requirement was six units of packed red cells (PRBC), each unit having tested negative for routine bacterial, viral and protozoan infections.

Post-operatively, the donor had a fever spike



(103°F) on second post-operative day (POD), with associated drop in hemoglobin (Hb) and platelet (PLT) count. Blood and urine cultures done came back negative. Serum procalcitonin was elevated at 2.76. By POD 4, there was afebrile thrombocytopenia, PLT count (28,000). Dengue profile was sent, which showed NS1 antigen positivity. Hence under the supervision of Infectious disease expert, he was started on supportive therapy for dengue. Platelets persistently fell (14,000) despite therapy.

On POD 9, he had sudden drop in Hb with hemorrhagic discharge from wound. PLT remained to be under 50,000 and he was thus transfused with packed red blood cells (PRBC) and single donor platelet (SDP) concentrates. He gradually responded to the above therapy and thereafter had an uneventful recovery period with no further drop in Hb or PLT counts. Donor was discharged healthy after a prolonged stay of 14 days.

The recipient, who was started on routine steroid and Tacrolimus immune-suppressive regime from POD 1, had similar incidents during his post-operative period. The PLT count witnessed a drop on POD 4 with associated rise in transaminases, without mounting a febrile response. Over the next two days, PLT count fell to as low as 13,000 with normal white cell counts. Intravenous Ganciclovir was started suspecting CMV infection. However, with no signs of clinical or hematological improvement, and simultaneously noting similar clinical occurrence in the donor as well, a Dengue profile was sent, which showed NS1 positivity for the recipient as well. The immune-suppression regime had mitigated the fever response, and thus made diagnosis difficult. He was also given supportive therapy, and required multiple PLT concentrate transfusions to overcome the acute stage. During the course of therapy, PLT counts returned to normal and liver functions stabilized by about POD 12. He overcame this episode, but later on in the course of hospital stay, he developed upper gastro-intestinal (GI) bleed requiring endotracheal intubation and ventilatory support. He then developed acute respiratory distress syndrome (ARDS), which soon progressed to multi-organ dysfunction syndrome (MODS), and he succumbed to illness on POD 30.

Discussion

Donor-derived disease transmission is reported to occur in less than 1% of transplants.³ Allograft donor-derived dengue viral transmission has been reported previously in living related renal transplants⁴, and is slowly creeping its way into living donor liver transplants as well, with two reports so far from North India^{2,5}; a region known to be hyper-endemic to the disease, with increased frequency of outbreaks and ever changing circulating serotypes of the virus.

The transplant recipient, under the influence of immune-suppression, may not mount a febrile response. A close follow up of laboratory parameters would be required to ascertain the diagnosis. The atypical presentation in our case, of afebrile thrombocytopenia and elevated transaminases can be mistaken for acute cellular rejection or CMV infection. Accurate diagnosis of dengue required a concurrent detection of infection in the donor, thereby raising suspicion of disease transmission during organ transplant. Considering the average incubation period of dengue illness is between two to seven days, and that the donor is usually admitted one day prior to day of surgery, it is most likely that initial exposure to the virus happened in the community. Since it is nearly impossible to acquire any infection from the nearly sterile environment maintained within organ transplant intensive care units (ICU, donor to recipient transmission is the most plausible explanation.

SUNEED KUMAR
SHAILESH SABLE
KAPILDEV YADAV
SWAPNIL SHARMA
ASHUTOSH CHOUHAN
SORABH KAPOOR
VIBHA VARMA
TANU SINGHAL
VINAY KUMARAN

*HPB & Liver Transplant,
Kokilaben Dhirubhai Ambani Hospital,
Andheri (W), Mumbai*

*Corresponding Author: Dr Suneed Kumar
Email: suneed.kumar@gmail.com*

References

1. Davila PM, Fortun J, Velez RL, Norman F, de Oca MM, Zamarron P et al. Transmission of Tropical and Geographically restricted infections during Solid-Organ Transplantation. *Clinical Microbiology Reviews*. Jan 2008; 21(1): 60-96
2. Saigal S, Choudhary NS, Saraf N, Kataria S, Mohanka R, Soini AS. Transmission of Dengue Virus From a Donor to a Recipient After Living Donor Liver Transplantation. *Liver*

Transplantation 2013; 19:1413–1414.

3. Ison MG, Nalesnik MA. An Update on Donor-Derived Disease Transmission in Organ Transplantation. *American Journal of Transplantation* 2011; 11: 1123–1130
4. Tan FLS, Loh DLSK, Prabhakaran K. Dengue haemorrhagic fever after living donor renal transplantation. *Nephrol Dial Transplant*. 2005; 20: 447–448.
5. Gupta RK, Gupta G, Chorasiya VK, Bag P, Shandil R, Bhatia V, Wadhawan M, Vij V, Kumar A. Dengue Virus Transmission from Living Donor to Recipient in Liver Transplantation: A Case Report. *Journal of Clinical and Experimental Hepatology*. 2016; 6:1: 59–61

Carcinoma Gall Bladder with Cardiac Metastasis Presenting as Liver Abscess: An Unusual Case

Carcinoma Gall Bladder (CaGB) is the most common biliary tract malignancy with geographic and ethnic disparities. It is one of the most common malignancies in north India, particularly in females. It has a vague presentation and mostly is detected in advanced stage. We here in report an interesting case which initially presented as liver abscess and latter diagnosed as gall bladder cancer with cardiac metastasis.

Case Report

A 55 year old gentleman presented to us with persistent fever and pain abdomen for the last one and half months. He was evaluated elsewhere with USG and CECT of the abdomen. A diagnosis of liver abscess was made and he was treated with antibiotics and percutaneous catheter drainage of the abscess cavity. The catheter was removed after three days. He continued to be symptomatic and was given a long course of antibiotics. At presentation to

our hospital he was febrile, septic but hemodynamically stable, anicteric with no lymphadenopathy. Abdominal examination was unremarkable. Blood investigations revealed a raised total count of 21900 c/mm^3 , normal bilirubin and liver enzymes with raised Serum Alkaline Phosphatase. He was reassessed with CECT which showed a large partly exophytic relatively well defined necrotic heterogeneously enhancing mass lesion measuring approx. $9.6 \times 10.3 \times 9.9$ in segment IVA, IVB, V and VIII of liver with gall bladder embedded within the mass lesion (**Figure 1A and 1B**), with heterogeneously hypodense lesion measuring 2.7×2.3 cm in right ventricle (**Figure 1C and 1D**), suggestive of gall bladder cancer with intracardiac metastasis. Tumour markers were evaluated which showed CEA-23.19, CA 19-9 100.5. ECHO showed a 2.5×4.6 mm homogenous mass in the Right ventricular apex with no free mobility. FNAC from the gall bladder mass confirmed the diagnosis of gall bladder cancer. In view of his poor performance status he

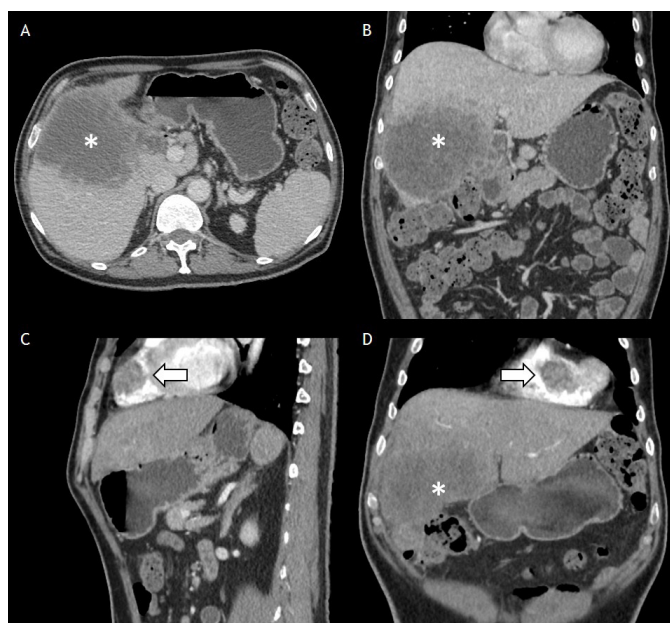


Figure 1(A & B): Thin venous phase image showing relatively well defined necrotic heterogeneously enhancing mass lesion measuring approx. $9.6 \times 10.3 \times 9.9$ in segment IVA, IVB, V and VIII of liver with gall bladder embedded within the mass lesion (asterisk mark). **(C & D):** Thin cut arterial phase imaging showing heterogeneously hypodense lesion measuring 2.7×2.3 cm in right ventricle- Intracardiac metastasis (arrow mark).