Tropical Gastroenterology 2009;30(4):230–232

Surgical Gastroenterology

Clinicopathological review of schistosomal appendicitis in south western Nigeria

AO Adisa[1], AE Omonisi[2], SA Osasan[2], OI Alatise[1]

Department of Surgery[1] and Morbid Anatomy[2]
Obafemi Awolowo University Teaching Hospitals Complex
PMB 5538, Ile-Ife, Nigeria.

Correspondence:
Dr. Adewale O Adisa
E-mail: wadisc@yahoo.com

ABSTRACT

Background: Gastrointestinal schistosomiasis may involve the appendix and there is no specific clinical picture associated with the same.
Methods: The clinical records and histopathological slides of all patients diagnosed with schistosomal appendicitis between January 1989 and December 2006 in Ile-Ife, south west Nigeria, were reviewed.
Result: Of 956 patients who had appendectomy at the Obafemi Awolowo University Teaching Hospital within the study period, 22 (2.3%) had histopathological diagnosis of schistosomal appendicitis. Eighteen (81.8%) were male whilst 4 (18.2%) were female. Their ages ranged between 15 and 63 years with a mean of 28.2 ($\pm$5.6) years. The mean duration of right lower quadrant abdominal pain was 4.2 years. Appendiceal and periappendiceal adhesions were noted intraoperatively in 17 (77.3%) and the appendix was adjudged grossly inflamed in 9 (40.9%) patients. Submucosal fibrosis and eosinophilia were the common histopathological findings aside from submucosal oviposition. All patients received antischistosomal drugs and one patient developed adhesive intestinal obstruction 9 months after surgery.
Conclusion: Schistosomal appendicitis may present acutely but diagnosis is only reliably made at histopathological examination. Adequate follow-up is however required to ascertain long-term outcome

KEYWORDS: schistosomiasis, appendicitis, treatment, outcome

Introduction

Schistosomal infections are on the increase in some endemic areas across Africa.[1,2] This chronic granulomatous infection, induced by ova deposition, may involve different parts of the gastrointestinal tract; the ileocaecal region is one of the most common sites involved. The appendix may be involved in up to two-thirds of cases; however the clinical manifestation varies widely amongst patient.[3,4] The resulting ova deposition in the appendix usually leads to the development of a proliferative granulomatous response especially within the mucosal and submucosal layers of the appendix along with submucosal lymphoid hyperplasia.[3,5,6] The granulomas may later be replaced by varying degrees of submucosal fibrosis.[5,7] At any of these stages, the patient may present with features of acute appendicitis.

This study reviews the clinical features as well as the operative and pathological findings in patients with schistosomal appendicitis in our hospital.

Methods

This study was conducted at Obafemi Awolowo Teaching Hospitals Complex Ile-Ife which is located in Osun state and serves the health needs of the urban and largely agrarian population of some parts of southwestern Nigeria. It serves as a referral centre to many hospitals in Ondo, Ekiti, Oyo and Osun states. The clinical records of all patients who had undergone appendectomy following a clinical diagnosis of acute or subacute appendicitis at the Ife Hospital unit of the Obafemi Awolowo University Teaching Hospital Complex in south western Nigeria between January 1989 and December 2006 (15-year period) were reviewed. Preoperative clinical features, investigation and intra-operative findings as well as the pathologist's reports of the histological slides indicating schistosomal appendicitis were also reviewed. Data extracted were subjected to descriptive analysis using the Statistical Package for Social Sciences (SPSS) version 13.

© Tropical Gastroenterology 2009

Results

Within the study period, a total of 956 patients underwent appendectomy for acute and subacute appendicitis. Of these 22 (2.3%) had schistosomal appendicitis. They were 18 male and 4 female patients with an age range of 15-16 years (Mean: 28.2 years). Half of the patients including all 4 females were 25 years or less in age (**Table 1**).

All patients suffered right lower quadrant abdominal pain. Other associated symptoms include nausea in 8 (36.4%), fever in 7 (31.8%) and vomiting in 3 (13.6%) as shown in **Table 2**. Varying degrees of tenderness in the right lower quadrant of the abdomen were recorded in 18 of the patients. However, the duration of different symptoms ranged between 2 days to 3 weeks with a mean duration of 14 days.

Preoperative differential white cell count demonstrated eosinophilia in two-thirds of the patients, lymphocytosis in one half of them and neutrophilia in 9.1%. All patients had abdominal ultrasound which reported right iliac fossa probe tenderness in 10 (45.5%), periappendiceal fluid collection in 7 (31.8%), appendiceal wall thickening in 5 (22.7%) and hepatomegaly in one patient. Subsequently, emergency open appendectomy was done in 15 patients whilst 7 patients who presented with longer duration of symptoms had elective procedures. Intraoperative findings include appendiceal and periappendiceal adhesions in 11 (50%), mesoappendiceal lymphadenopathy in 3, and the appendix was adjudged to be grossly inflamed in 9 (40.9%) patients. Only one patient had postoperative wound infection in the form of a stitch sinus. On receiving the histopathological report, all patients underwent treatment with a single 60 mg/kg dose of oral praziquantel. Duration of follow up ranged between one and 12 months with a mean of 2.2 months. One female patient presented with features of adhesive intestinal obstruction 9 months after surgery and did well on conservative management.

A review of the histopathological slides of the patients revealed schistosomal ova in the submucosal layer in all patients [**Figures 1 and 2**]. Ova were also seen in the muscularis propria and serosal layers in 7 (31.8%) patients. Submucosal eosinophilia was noted in 20 (90.9%) and submucosal fibrosis in 16 (72.7%). Eight patients (36.4%) had suppurative inflammation whilst granulomas were seen in 13 (59.1%) patients.

Table 1: Age and gender of patients with schistosomal appendicitis

Age (years)	Sex	
	Male	Female
≤20	3	3
21-25	4	1
26-30	2	-
31-35	6	-
36-40	2	-
>40	1	-
Total	18	4

Table 2: Duration of symptoms

Presenting complaint		Duration of symptoms
	Frequency (%)	Mean (days)±SD
RLQ abdominal pain	22 (100)	14 ± 2.2
Nausea	8 (36.4)	11 ± 3.2
Fever	7 (31.8)	10 ± 2.3
Vomiting	3 (13.6)	6 ± 1.2
Diarrhoea	3 (13.6)	8 ± 1.4
Transient jaundice	1 (4.5)	2 days

RLQ - Right lower quadrant

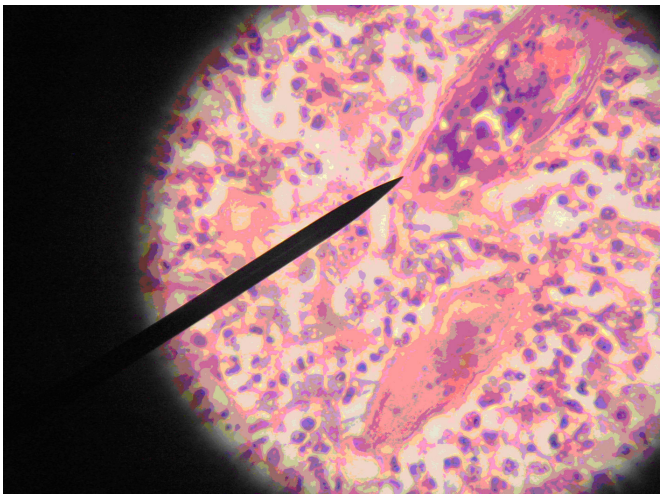

Figure 1: Parraffin embedded H&E stained specimen, X40 magnification showing multiple ova with background eosinophilia

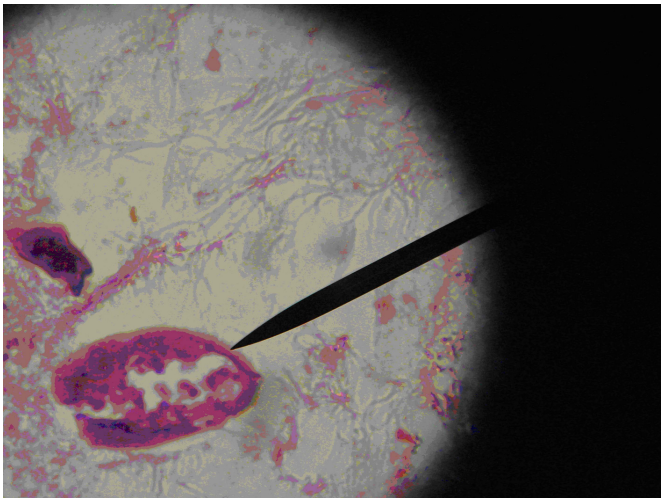

Figure 2: Parraffin embedded H & E stained specimen, X40 magnification showing schistosomal ova with background calcification

Discussion

In this study, schistosomal appendicitis occurred in 2.3% of patients with acute appendicitis. This is relatively higher compared to 1.5%[5] and 1.3% from different regions of Saudi Arabia,[4] but is lower than 3.5% reported from Dar'es Salam in Tanzania.[8] The true incidence of schistosomal infestation in the south western region of Nigeria is not known and this finding may point towards a high prevalence rate. Similar to findings in previous reports,[4,5,9] a male predominance with a mean age of 28.2 years was observed in this study. A similar mean age was seen in the African-American patient population.[10] In our own developing economy, young male patients are more involved in outdoor occupations especially with a large proportion of our patients being farmers with a higher probability of exposure to schistosomiasis than the female population or the older age groups.

All patients presented with features suggestive of acute appendicitis and complaints of right lower quadrant abdominal pain of varying duration. Although a mean duration of symptoms of 14.2 days before presentation is relatively higher than what we have observed in our patients with non-schistosomal acute appendicitis, no other symptom or signs in the patients pointed

to schistosomiasis preoperatively. This is in keeping with reports of previous studies.[11-13] The investigations carried out on our patients were mainly those for diagnosis of routine acute appendicitis and it is not surprising that diagnosis of schistosomal appendicitis was not entertained in any of the patients, preoperatively. Microscopic examination of a fresh rectal biopsy is helpful in diagnosing acute gastrointestinal schistosomal infestation and this would have been of value in distinguishing acute from chronic schistosomal conditions with implications for treatment following surgery, but this was not done in our patients.

Findings on review of the histopathologic slides show features suggestive of chronic schistosomal infection of the appendix in many patients. These include submucosal fibrosis in about three-quarters of the studied specimen. This is similar to the report of a previous study in Saudi Arabia on schistosomal appendicitis highlighting submucosal fibosis as a very common finding.[5] The other common features include submucosal lymphoid hyperplasia or atrophy and submucosal or serosal granuloma.[14,15] Many studies had questioned the relevance of schistosomiasis in appendicitis with some authors postulating that it may actually be a mere histological coincidence.[16-18] However in the majority of our patients, a history of abdominal pain suggests chronicity of the condition. The histopathological slides also show chronic inflammatory cells and fibrosis commonly seen in chronic appendicitis. It may therefore be that previously existing schistosomal infestation induces a chronic inflammatory process in the appendix as in other parts of the gastointestinal tract but the resultant fibrosis and stricture formation with partial luminal obstruction of the appendix may present as acute appendicitis to the surgeon.

The average duration of follow up was 2.2 months. One female patient presented with adhesive intestinal obstruction eight months after surgery. She had stopped attending the out-patients' clinic for six months before re-presenting. She was however managed conservatively and did well subsequently. The long-term outcome of other patients could not be ascertained.

Conclusion

Schistosomal appendicitis is rare but may present acutely. For a reliable diagnosis histopathological examination is a prerequisite. The outcome of surgery and treatment is good if patients are treated promptly.

References

1. Duvie SOA, Diffang C, Guiguis MN. The effect of schistosoma haematobium infestation on the vermiform appendix: the Nigerian experience. *J Trop Med Hyg*. 1987;**90**:13–8.
2. Adebamowo CA, Akang EE, Ladipo JK, Ajao OG. Schistosomiasis of the appendix. *Br J Surg*. 1991;**78**:1219–21.
3. Gelfand M, Ross CM, Blair DM, Castle WM, Weber MC. Schistosomiasis of the male pelvic organs. Severity of infection as determined by digestion of tissues and histologic methods in 300 cadavers. *Am J Trop Med Hyg*. 1970;**19**:779–84
4. Abu-Eshy SA, Malik GM, Khan AR, Khan GM, Al-Shehri MY. Schistosomal appendicitis. *Ann Saudi Med*. 1995;**15**:347–9.
5. Meshikhes AW, Chandrashekar CJ, Al-Daolah Q, Al-Saif O, Al-Joaib AS, Al-Habib SS, et al. Schistosomal appendicitis in the Eastern Province of Saudi Arabia: A clinicopathological study. *Ann Saudi Med*. 1999;**19**:12–4.
6. Bell DR. Blood flukes- schistosomes. In: Lecture notes on tropical medicine. London: *Blackwell Scientific*, 1981:187–209.
7. Hodasi M. Schistosomal appendicitis. *Trop Doct*. 1988;**18**:105–6.
8. Mbembati NA, Lema LE, Mwakyoma HA, Ussiri EV. Appendicitis in Dar'es Salaam, histological pattern. *Cent Afr J Med*. 1996;**42**:68–70.
9. Al-Kraida A Giangreco A, Shaikh MU, Al-Shehri MY. Schistosomal appendicitis. *Br J Surg* 1988;**75**:58–60.
10. Nandipati K, Parithivel V, Niazi M. Schistosomiasis: a rare cause of acute appendicitis in the African American population in the United States. *Am Surg*. 2008;**74**:221–3.
11. Lowenthal MN. Schistosomal appendicitis. *Isr Med Assoc J*. 2005;**7**:679.
12. Khan GM, Grillo IA, Abu-Eshy SA, Khan AR, Mubarak J, Jastaniah S. Pathology of the appendix. *J Natl Med Assoc*. 2000;**92**:533–5.
13. Adehossi E, Parola P. Schistosomal appendicitis. *Lancet Infect Dis*. 2004;**4**:498.
14. Babekir AR, Devi N. Analysis of the pathology of 405 appendices. *East Afr Med J*. 1990;**67**:599–602.
15. Ojo OS, Udeh SC, Odesanmi WO. Schistosomiasis of the appendix. Review of the histopathological findings in appendices removed for acute appendicitis in Nigerians. *J R Coll Surg Edinb*. 1991;**36**:245–8
16. Satti MB, Tamimi DM, Al Sohaibani MO, Al Quorain A. Appendicular schistosomiasis: a cause of clinical acute appendicitis? *J Clin Pathol*. 1987;**40**:424–8.
17. Doudier B, Parola P, Dales JP, Linzberger N, Brouqui P, Delmont J. Schistosomiasis as an unusual cause of appendicitis. *Clin Microbiol Infect*. 2004:**10**:89–91.
18. Kakande I, Nehra MK. Appendicectomy in Consolata Hospital, Nyeri: analysis of operative and histological findings. *East Afr Med J*. 1990;**67**:573–7.