Tropical Gastroenterology 2009;30(4):222–225

An Unusual Case of Intestinal Obstruction

Case Report

A 40-year-old man presented with complaints of colicky abdominal pain of 3 days duration associated with vomiting and constipation. He had previously undergone 2 surgeries; an appendectomy 5 years ago and repair of enteric perforation 1 month earlier. Clinical examination revealed dehydration, a poorly healed midline scar with a 3 cm x 3 cm defect near the umbilicus and a distended abdomen with exaggerated bowel sounds. Plain abdominal radiograph revealed multiple air fluid levels. Ultrasound study of the abdomen revealed dilated hyperperperistaltic bowel loops and minimal free fluid in the right iliac fossa. A presumptive diagnosis of adhesive small bowel obstruction was made and the patient was made nil per oral, and subjected to nasogastric suction and parenteral fluids. As he failed to improve despite 48 hours of conservative management, he was taken up for laparotomy. Peroperative findings revealed minimal ascites, gross thickening of the ileocaecal mesentery, dense adhesions of the terminal ileum, caecum and ascending colon to the parietes and to each other; multiple interloop adhesions; and a 6 cm x 5 cm abscess cavity in the right upper abdomen. Adhesiolysis, drainage of abscess cavity, ileocaecal resection, ileostomy and mucus fistula was done. The patient developed ileostomy diarrhoea in the early postoperative period which was managed with high fibre diet, antimotility agents and fluid supplementation, respectively. On the tenth postoperative day, the patient developed features suggestive of septicemic shock necessitating mechanical ventilation and aggressive resuscitation measures. Ultrasound study of the abdomen did not reveal any collection. As blood culture was non contributory, we performed culture of the ileostomy effluent which grew *Klebsiella* sensitive only to carbapenems. The patient responded to imipenem which was administered for 2 weeks. He was weaned off the ventilator, allowed normal diet and subsequently discharged. Histopathology of the resected specimen revealed gross thickening of the mesentery of the resected bowel (**Figure1**). Microscopic examination revealed septal inflammation (**Figure 2**), mesenchymal proliferation (**Figure 3**), foreign body giant cell reaction (**Figure 4**) and vasculitis (**Figure 5**) consistent with mesenteric panniculitis. Three months later, the patient underwent an uneventful restoration of continuity.

Figure 1: Gross thickening of the mesentery

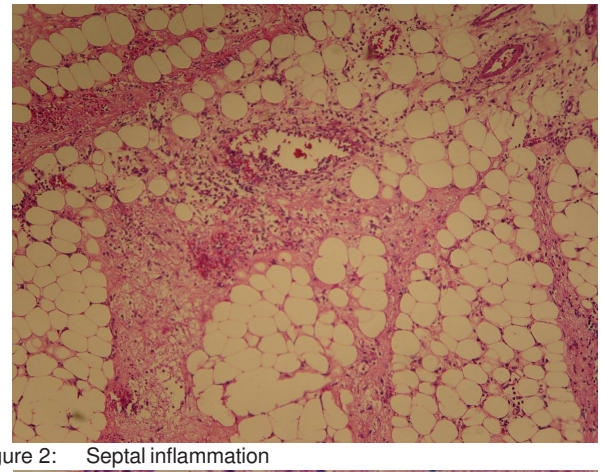

Figure 2: Septal inflammation

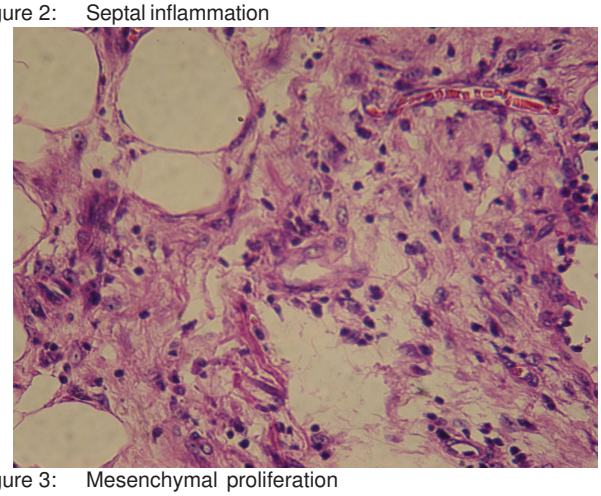

Figure 3: Mesenchymal proliferation

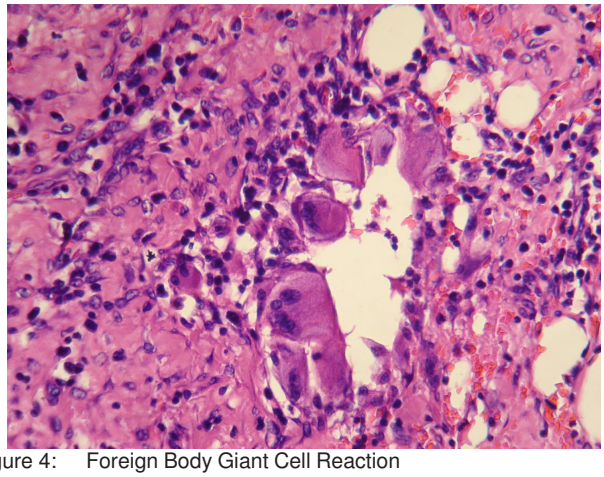

Figure 4: Foreign Body Giant Cell Reaction

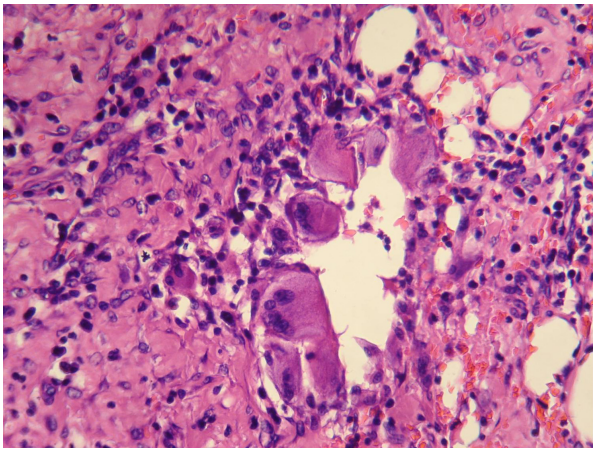

Figure 5: Vasculitis

Discussion

Mesenteric panniculitis is a poorly understood entity which was first described by Jura as "retractile mesenteritis" in 1924.[1] The term mesenteric panniculitis was coined by Ogden.[2] Known by a variety of terms including isolated lipodystrophy,[3] mesenteric manifestation of Weber Christian disease[4] and mesenteric lipogranuloma,[5] it has been described as an idiopathic inflammatory and fibrotic process which primarily affects the small bowel mesentery. According to recently published literature, involvement of the colonic mesentery is very rare.[6,7] Other sites of involvement include the peripancreatic region, omentum, retroperitoneum and pelvis.[8,9,10,11] Less than 300 cases have been described worldwide till date.[12] Predominantly occurring in middle-aged individuals, this condition has a slight male predilection. The proposed aetiological factors of this disease include blunt trauma, prior surgery, allergic disease, autoimmune processes, cold, drugs, vitamin deficiency and vasculitis.[13] Rarely, abdominal tubercular lymphadenitis and autoimmune hemolytic anaemia have been implicated in the pathogenesis of this condition.[14,15] Some authors have proposed that mesenteric panniculitis represents one phase in a continuum of pathological inflammatory changes affecting the small bowel mesentery. Initially, there is degeneration of mesenteric fat i.e lipodystrophy followed by inflammation (panniculitis). Later, fibrosis develops and it is then termed retractile mesenteritis.[16,17,18] Whether retractile mesenteritis and retroperitoneal fibrosis represent two different disease entities or the same pathological process is a subject of controversy.[19,20] Clinical features include abdominal pain, back pain, intermittent fever, weight loss, anorexia, vomiting, constipation, diarrhoea, bowel obstruction and occasionally, rectal bleeding while half of the patients present with a poorly defined abdominal mass.[21,22,23] Sclerosing mesenteritis rarely presents as chylous ascites.[24] Mesenteric panniculitis has been known to masquerade as intra-abdominal malignancy, retroperitoneal mass, chronic pancreatitis and even pancreatic cyst. Although a preoperative diagnosis is rarely established, certain characteristic findings on CT scan may provide a clue to the disease. The imaging appearances vary depending on the predominant tissue component (fat necrosis, inflammation or fibrosis).[25] The common findings in mesenteric panniculitis include hazy mesenteric infiltration ("misty mesentery") especially of the jejunal mesentery with discrete margins and relative sparing of perivascular fat ("fat-

ring sign"). In 50% of cases, a tumour pseudo capsule ("pseudotumoural stripe") may be present.[26,27] On CT follow up, progression of mesenteric panniculitis to fibrosis has been documented in literature.[28] In our case, we mistakenly presumed adhesions to be the cause of intestinal obstruction and hence, did not obtain a CT scan. The role of CT scan is not only confined to the diagnosis of this entity, but also non invasive follow up of the volume, extent, vascular involvement of the mass and identification of potential complications. Radiological differential diagnoses include carcinomatosis, carcinoid tumour, lymphoma, mesenteric oedema and primary mesenteric mesothelioma.[29] Angiography, MRI and positron emission tomography have also been used to detect this clinical entity.[30] The majority of cases however, are diagnosed on histopathological examination. The pathological findings range from fatty infiltration of the mesentery and microscopic infiltration of the fat by lymphocytes, macrophages and foreign body giant cells to a retracted, scarred and adherent mesentery with fat necrosis, fibrosis and calcification.[2] The former pattern was noted in our case. The disease has a benign course although an association with malignancy, especially lymphoma has been noted by some authors.[31,32] There is no consensus on the management of patients with mesenteric panniculitis. Patients with minimal symptoms may be followed up with imaging whereas those presenting acutely with intestinal obstruction may require resection, excision or diversion. In our case, following resection, the patient developed septicemia probably as a result of *Klebsiella* enteritis which manifested as ileostomy diarrhoea and shock. The diagnosis was established by culture of ileostomy effluent and the patient was given appropriate antibiotics which resulted in a good outcome. A thorough search of indexed medical literature failed to reveal previous reports of *Klebsiella* enteritis manifesting as septicemic shock. There are a few case reports of good response of mesenteric panniculitis to antibiotics, tamoxifen, pentoxifylline, colchicine, oral progestogens, steroids and immunosuppressants.[15,21,33,34,35,36]

Conclusion

We have presented a case of mesenteric panniculitis which presented with intestinal obstruction. The acute presentation warranted surgical exploration. However, a preoperative diagnosis may have been made with a CT scan of the abdomen. The patient had a stormy postoperative period due to *Klebsiella* enteritis and septicemia, which was successfully diagnosed by culture of the ileostomy effluent. This case highlights the need to consider alternative causes of intestinal obstruction other than adhesions in a patient who have a history of prior surgical intervention. The role of CT scan in the diagnosis of mesenteric panniculitis as well as the importance of ileostomy fluid cultures in the diagnosis of unexplained septicemic shock in patients with ileostomy diarrhoea have also been emphasised.

References

1. Jura SV. Mesenterile Retrattile e Sclerosante. *Policlinica (Sez Prat)*. 1924;**31**:575.
2. Ogden WW, Bradburn DM, Rives JD. Panniculitis of the mesentery. *Ann Surg*. 1960;**151**:659–68.
3. Crane JT, Aguilar MJ, Grimes OF. Isolated lipodystrophy, form of mesenteric tumor. *Am J Surg*. 1955;**90**:169–79.
4. Herrington JL, Edwards WH, Grossman LA. Mesenteric manifestation of Weber Christian Disease. *Ann Surg*. 1961;**154**:949–55
5. Weeks LE, Block MA, Hathaway JC, Rinaldo JA. Lipogranuloma of mesentery producing abdominal Mass. *Arch Surg*. 1963;**86**:615–20.
6. Wexner SD, Attiyeh FF. Mesenteric panniculitis of the sigmoid colon. Report of two cases. *Dis Colon Rectum*. 1987;**30**:812–5.
7. Karentzos S, Tzoutzos D, Stavropoulos G, Giannakou N, Gkiconti I, Giannakakis A. [Mesenteric panniculitis of the sigmoid colon. A case report and review of the literature.] [Article in Italian] *Minerva Chir*. 1990;**45**:1403–6.
8. Akram S, Pardi DS, Schaffner JA, Smyrk TC. Sclerosing mesenteritis: Clinical features, treatment and outcome in ninety two patients. *Clin Gastroenterol Hepatol*. 2007;**5**:589–96.
9. Emory TS, Monihan JM, Carr NJ, Sobin LH. Sclerosing mesenteritis, mesenteric panniculitis and mesenteric lipodystrophy: a single entity? *Am J Surg Pathol*. 1997;**21**:392–8.
10. Vettoretto N, Diana DR, Poiatti R, Matteucci A, Chioda C, Giovanetti M. Occasional finding of Mesenteric lipodystrophy during laparoscopy: A difficult diagnosis. *World J Gastroenterol*. 2007;**13**:5394–6.
11. Kishimoto K, Hokama A, Irei S, Aoyama H, Tomiyama R, Hirata T, et al. Chronic diarrhoea with thickening of the bowel wall. *Gut*. 2007;**56**:94–114.
12. Grieser C, Denecke T, Langrehr J, Hamm B, Hanninen EL. Sclerosing mesenteritis as a rare cause of upper abdominal pain and digestive disorders. *Acta Radiol*. 2008;**23**:1–3.
13. Popkharitov AI, Chomov GN. Mesenteric panniculitis of the sigmoid colon: a case report and review of the literature. *J Med Case Reports*. 2007;**1**:108.
14. Ege G, Akman H, Cakiroglu G. Mesenteric panniculitis associated with abdominal tuberculous lymphadenitis: a case report and review of the literature. *Br J Radiol*. 2002;**75**:378–80.
15. Papadaki HA, Kouroumalis EA, Stefanaki K, Roussomoustakaki M, Daskalogiannaki M, Reppa D, et al. Retractile mesenteritis presenting as fever of unknown origin and autoimmune Haemolytic anaemia. *Digestion*. 2000;**61**:145–8.
16. Thompson GT, Fitzgerald EF, Somers SS. Retractile mesenteritis of the sigmoid colon. *Br J Radiol*. 1985;**58**:266–7.
17. Hartz R, Stryker S, Sparberg M, Poticha SM. Mesenteric tumefactions. *Am Surg*. 1980;**46**:525–9.
18. Aach RD, Kahn LI, Frech RS. Obstruction of the small intestine due to retractile mesenteritis. *Gastroenterology*. 1968;**54**:594–8.
19. Durst AL, Freund H, Rosenmann E, Birnbaum D. Mesenteric panniculitis. Review of the literature and presentation of cases. *Surgery*. 1977;**81**:203–11.
20. Bush RW, Hammar SP, Rudolph RH. Sclerosing mesenteritis. Response to cyclophosphamide. *Arch Intern Med*. 1986;**146**:503–5.
21. Mazure R, Fernandez Marty P, Niveloni S, Pedreira S, Vazquez H, Smecuol E, et al. Successful treatment of retractile mesenteritis with oral progesterone. *Gastroenterology*. 1998;**114**:1313–7.
22. Parra-Davila E, McKenney MG, Sleeman D, Hartmann R, Rao RK, McKenney K, et al. Mesenteric panniculitis: Case report and literature review. *Am Surg*. 1998;**64**:768–71.
23. White B, Kong A, Chang AL. Sclerosing mesenteritis. *Australas Radiol*. 2005;**49**:185–8.
24. Arora M, Dubin E. A Clinical Case Study: Sclerosing mesenteritis presenting as chylous ascites. *Medscape J Med*. 2008;**10**:30.
25. Mata JM, Inaraja L, Martin J, Olazabal A, Castilla MT. CT features of mesenteric panniculitis. *J Comput Assist Tomogr*. 1987;**11**:1021–3.
26. Mindelzun RE, Jeffrey RB, Lane MJ, Silverman PM. The misty mesentery on CT: Differential Diagnosis. *Am J Roentgenol*. 1996;**167**:61–5.
27. Sabate JM, Torrubia S, Maideu J et al. Sclerosing mesenteritis: imaging finding in 17 patients. *Am J Roentgenol* 1999;**172**:625–9
28. Kelly JK, Hwang WS. Idiopathic retractile (sclerosing) mesenteritis

and its differential diagnosis. *Am J Surg Pathol*. 1989;**13**:513–21.
29. Hamrick-Turner JE, Chiechi MV, Abbitt PL, Ros PR. Neoplastic and inflammatory processes of the peritoneum, omentum and mesentery: diagnosis with CT. *Radiographics*. 1992;**12**:1051–68.
30. Ghanem N, Pache G, Bley T, Kotter E, Langer M. MR findings in a rare case of sclerosing Mesenteritis of the mesocolon. *J Magn Reson Imaging*. 2005;**21**:632–6.
31. Kipfer RE, Moertel CG, Dahlin DC. Mesenteric lipodystrophy. *Ann Intern Med*. 1974;**80**:582–8.
32. Harris RJ, van Stolk RU, Church JM, Kavuru MS. Thoracic mesothelioma associated with abdominal mesenteric panniculitis. *Am J Gastroenterol*. 1994;**89**:2240–2.
33. Venkataramani A, Behling CA, Lyche KD. Sclerosing mesenteritis: an unusual cause of abdominal Pain in an HIV positive patient. *Am J Gastroenterol*. 1997;**92**:1059–60.
34. Kapsoritakis AN, Rizos CD, Delikoukos S, Kyriakou D, Koukoulis GK, Potamianos SP. Retractile Mesenteritis presenting with malabsorption syndrome: Successful treatment with oral Pentoxifylline. *J Gastrointest Liver Dis*. 2008;**17**:91–4.
35. Genereau T, Bellin MF, Wechsler B, Le TH, Bellanger J, Grellet J, et al. Demonstration of efficacy of combining corticosteroids and colchicines in two patients with idiopathic sclerosing mesenteritis. *Dig Dis Sci*. 1996;**41**:684–8.
36. Bala A, Coderre SP, Johnson DR, Nayak V. Treatment of sclerosing mesenteritis with steroids and Azathioprine. *Can J Gastroenterol*. 2001;**15**:533–5.

VIJAY RAMACHANDRAN
BV VYDEHI
Corresponding Author: Dr. Vijay Ramachandran
Department of Surgical Gastroenterology
Narayana Medical College & Hospital, Chinthareddypalem
Nellore. Andhra Pradesh – 524002
Email: drvijayr@gmail.com