forms of chronic liver disease and to confirm the diagnosis of NAFLD.[5] Other features such as hypercholesterolemia, and high LDL - cholesterol were also commonly found[6] as seen in our patients where one patient had high cholesterol and the other had high triglycerides. However, they had atypical features, including age of presentation, consanguinity, developmental delay, with a normal weight for age.

Pediatric NAFLD has a distinct histopathological pattern of disease, which is characterized mainly by presence of predominantly portal based injury. It is referred to as type 2 or pediatric NASH to differentiate it from typical zone 3 pattern of disease, which is known as type 1 NASH. However, it was seen that a vast majority of patients had overlapping features of both type 1 adult NASH and type 2 pediatric NASH.[7] Other parameters such as measuring specific circulating markers of fibrogenesis or fibrosis, or changes in tissue elasticity appear to be more promising techniques for staging disease in pediatric NAFLD.[8,9]

In a follow up study of non-alcoholic fatty liver disease in children for upto 20 years, Feldstein et al concluded that NAFLD is a disease of progressive potential in children with a significantly shorter long term survival as compared to the general population of the same age and sex. NAFLD in children may progress to cirrhosis and end stage liver disease with the consequent need for liver transplantation, but NAFLD with severe NASH may recur in the allograft.[6]

In conclusion, NASH needs to be suspected in cases of children with persistently elevated aminotransferases and further studies need to be conducted in India assess the prevalence of NASH.

MARY JOSEPH
IRA SHAH

Pediatric Liver Clinic, B.J.Wadia Hospital for Children, Mumbai, India.

Correspondence: Ira Shah
Email: irashah@pediatriconcall.com

References

1. Sass DA, Chang P, Chopra KB. Non alcoholic fatty liver disease: A clinical review. *Digestive Diseases and Sciences*. 2005;**50**:171-180.
2. Ludwig J, Viggiano TR, McGill DB, Oh BJ. Non alcoholic steatohepatitis: *Mayo Clinic proc*. 1980;**55**:434-438.
3. Baumann U. Brown R. Non alcoholic fatty liver disease in childhood. *Br J Diabetes Vasc Di*s. 2006;**6**:264-268.
4. Schwimmer JB, Deutsch R, Kahen T, Lavine JE, Stanley C, Behling C. Prevalence of fatty liver in children and adolescents. *Pediatrics*. 2006;**118**:1388-1393.
5. Angulo P. Non alcoholic fatty liver disease. *N Engl J Med*. 2002;**346**:1221-1231.
6. Feldstein A E, Charatcharoenwitthaya P, Traprasertsuk S, Benson JT, Enders FB, Angulo P. The natural history of non- alcoholic fatty liver disease in children: a follow up studyfor upto 20 years. *Gut*. 2009;58:1538-1544.
7. Schwimmer JB, Behling C, Newbury R, Deutsch R, Nievergelt C, Schory NJ. Histopathology of pediatric non alcoholic fatty liver disease. *Hepatology*. 2005;**42**:641-649.
8. Nobili V, Parkes J, Bottazzo G et al. Performance of ELF serum markers in predicting fibrosis stage in Pediatric Non Alcoholic Fatty Liver Disease. *Gastroenterology*. 2009;**136**:160-167.
9. Nobili V, Vizzutti F, Alena U, Abraldes JG, Marra F, Pietrobattista A et al. Accuracy and reproducibility of transient elastography for the diagnosis of fibrosis in pediatric non alcoholic steatohepatitis. *Hepatology*. 2008;**48**:442-448.

Primary Ewing's sarcoma / primitive neuroectodermal tumor of stomach

Ewing's sarcoma (ES) is a small round cell tumor that arises most commonly in bones, and may occasionally originate in soft tissues. Extraskeletal Ewing's sarcoma (ESS) has the same genetic origin as ES, and may involve any part of body such as small bowel, vagina, esophagus,

pancreas or kidney.[1] It is relatively rare foran Ewing's sarcoma / Peripheral Neuroectodermal Tumor (PNET) to arise from the stomach. Only six cases of gastric ES/ PNET have been previously reported.

Case Report

A 32-year-old female presented with complaints of pain upper abdomen and loose stools since 2 months ago. CECT Abdomen showed an exophytic mass of 11x6.5 cm arising from the lesser curvature of the stomach (**Figure 1**). A case of GIST was suspected. Exploratory laparotomy with excision of mass was done. Histologic examination of the excised mass revealed undifferentiated small round cells arranged in groups and along blood vessels with mild pleomorphism, inconspicuous nuclei and scanty mitosis (**Figure 2**). Strong membranous CD 99 positivity was noted by immuno histo chemistry (IHC), which is essential for diagnosis of ES.[2] Vimentin was also found to be strongly positiveon IHC. S-100 showed focal positivity. Synaptophysin, chromogranin A, NSE, PLAP, AFP, inhibin, caretinin and desmin were negative. After surgery, PET scan showed an ill-defined nodular lesion in left breast upper outer quadrant showing low grade FDG uptake which was adjudged to be most likely benign. There were no other significant findings. The patient was given six courses of adjuvant chemotherapy comprising epirubicin (100 mg), cyclophosphamide (1000 mg) and vincristine (2mg) intravenously. Patient tolerated all cycles of chemotherapy well. After 6 courses of chemotherapy, PET scan showed a nodular lesion in deep subareolar region with increased FDG uptake. No abnormal FDG uptake was noted in stomach. Mammograph showed calcification in left breast. Biopsy from breast lesion was taken and was found to be negative for malignant cells. At present, patient is disease free after 1 year of surgery and is on regular follow up.

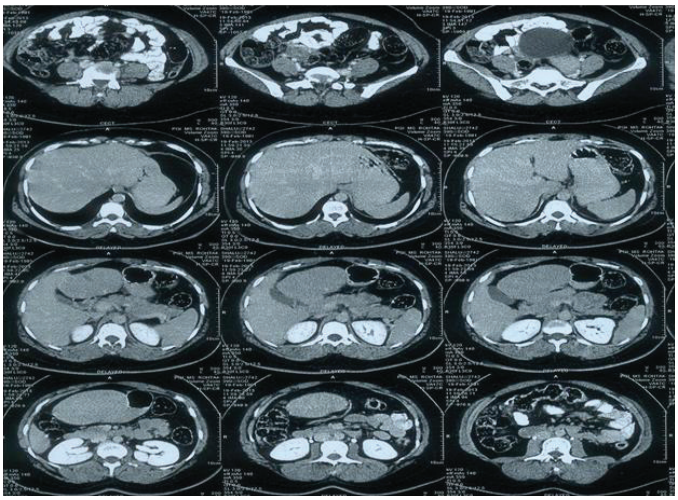

Figure 1: CECT Abdomen showed an exophytic mass of 11x65 cm arising from lesser curvature of stomach.

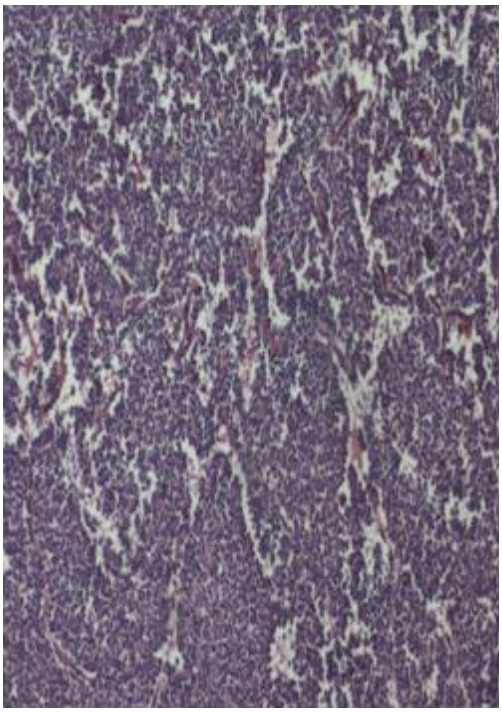

Figure 2: Photomicrograph showing sheets of small round tumor cells separated by blood vessels (HE, 200X).

Discussion

Ewing sarcoma and PNET are two variants of the same tumor. They differ only in the degree of neural differentiation. Both have similar neural phenotype, surface marker protein (CD99) and share an identical chromosome translocation - most commonly t(11;22). Tumors that demonstrate neural differentiation are labeled PNETs, while the rest are diagnosed as Ewing sarcoma[1]. The two diseases are now treated as a single entity.

Strong membranous CD 99 is essential for the diagnosis of ES/PNETs. Antibody to CD99 has been

strongly positive in 90 - 100% of cases reported to be ES/PNETs.[2] All six reported cases of gastric ES/PNETs also revealed the diagnostic significance of CD99. Vimentin which is an intermediate filament that is present in most mesenchymal cell is also usually positive in ES/PNET cells.[1] The six reported cases of gastric ES/PNETs also showed positive vimentin expression in tumor cells. In ES/PNET, various neural markers such as S100, chromogranin A, synaptophysin and neuron-specific enolase (NSE) shows variable immunohistochemical staining which may be due to the differing degrees of neuroectodermal differentiation in the individual tumors.[1]

Surgical resection was possible in all six reported cases of gastric ES/PNETs. The current standard chemotherapeutical treatment for ES/PNETs is a regimen comprising the drugs: vincristine, doxorubicin, cyclophosphamide, ifosfamide and etoposide. Chemotherapy has a curative role in the management of localized ES/PNET but its role in metastatic disease is limited.[3,4] Combined modality treatment comprising of surgery, multi agent chemotherapy and radiation therapy improves survival in metastatic ES/ PNET.[5]

DEEPAK KUMAR[1]
PARAMJEET KAUR[1]
ANIL KHURANA[1]
ASHOK K CHAUHAN[1]
RAJEEV SEN[2]

Department of Radiotherapy[1] & Pathology[2],
Pt. BDS, PGIMS Rohtak.

Correspondence: Deepak Kumar
Email: drparamjitkaur@rediffmail.com

Refernces

1. El Weshi A, Allam A, Ajarim D, Al Dayel F, Pant R, Bazarbashi S, et al. Extraskeletal Ewing's sarcoma family of tumours in adults: analysis of 57 patients from a single institution. *Clin Oncol (R CollRadiol)*. 2010;**22**:374-381.
2. Ramani P, Rampling D, Link M. Immunocytochemical study of 12E7 in small round-cell tumours of childhood: an assessment of its sensitivity and specificity. *Histopath*. 1993;**23**:557-561.
3. Leavey PJ, Collier AB. Ewing sarcoma: prognostic criteria, outcomes and future treatment. *Expert Rev Anticancer Ther*. 2008;**8**:617-624.
4. Esiashvili N, Goodman M, Marcus RB Jr. Changes in incidence and survival of Ewing sarcoma patients over the past 3 decades: Surveillance Epidemiology and End Results data. *J Pediatr Hematol Oncol*. 2008;**30**:425-430.
5. Haeusler J, Ranft A, Boelling T, Gosheger G, Braun-Munzinger G, Vieth V,et al. The value of local treatment in patients with primary, disseminated, multifocal Ewing sarcoma (PDMES) *Cancer*. 2010;**116**:443-450.