Tropical Gastroenterology 2009;30(4):219–220

Case Reports

Foreign body giant cell reaction mimicking recurrence of colon cancer

Introduction

Foreign substances, when introduced into the human body, may elicit inflammatory and foreign body giant cell reactions. Substances which may be introduced during surgery include talc, suture, sponge, gauze, lint, glove powder, hemostatic material, surgical clips, prosthetic implants, et cetera. Depending on the nature and the extent of the reaction elicited by these foreign substances, they may cause lesions accompanied by varying symptoms. There have been reports of surgically introduced foreign material causing lesions such as intra-abdominal adhesions (secondary to suture and talc granulomas),[1] tumour masses (textilomas or gossypibomas),[2] space-occupying lesions (especially in the brain)[3] or even lesions mimicking metastasis in cancer cases.[4] With this background in mind, we report a case with extensive post-operative foreign body giant cell reaction mimicking recurrence in an operated case of colon cancer.

Case history

A 45-year-old male patient diagnosed with carcinoma of the sigmoid colon, underwent left hemicolectomy with descending colon to rectum anastomosis and transverse loop colostomy in February 2008. Histopathology revealed features of moderately differentiated adenocarcinoma infiltrating into the serosa, with surgical margins free of tumour. One of the lymph nodes dissected from the specimen showed the presence of metastasis. The patient then received 5 cycles of chemotherapy. Post-operative recovery was uneventful.

A routine follow-up CT scan, performed in August 2008 revealed a circumferential mural thickening of the colonic wall in the region of the previously operated site. Colonoscopy showed a nodular, partial lumen occluding growth, 20 cm from the anal verge. The lesion bled on touch and strongly suggested recurrence of the carcinoma. Colonoscopic-guided biopsy from the lesion only revealed granulation tissue with no evidence of tumour; repeat biopsy was advised.

In view of the high degree of suspicion, exploratory laparotomy with resection of the involved bowel segment was performed. Intraoperatively, thickening of the wall in the region of the mid-descending colon was noted.

Grossly, the resected large bowel segment measuring 5 cm in length showed nodular thickening on the serosal aspect. The corresponding mucosal surface showed two discrete nodular lesions measuring 1.5 cm and 2 cm in diameter, respectively (**Figure 1**). The lesions displayed surface ulceration and the cut surface was white and firm in consistency. The histological sections from the nodules revealed ulceration of the colonic mucosa with dense aggregates of inflammatory cells, consisting of lymphocytes, plasma cells and numerous foreign body type giant cells (**Figure 2**). Amidst the inflammation, the suture material was identified within the cytoplasm of giant cells as well as lying extracellularly (**Figure 3**). In spite of extensive sampling of the resected specimen, no evidence of tumour was seen.The post-operative clinical course of the patient was uneventful.

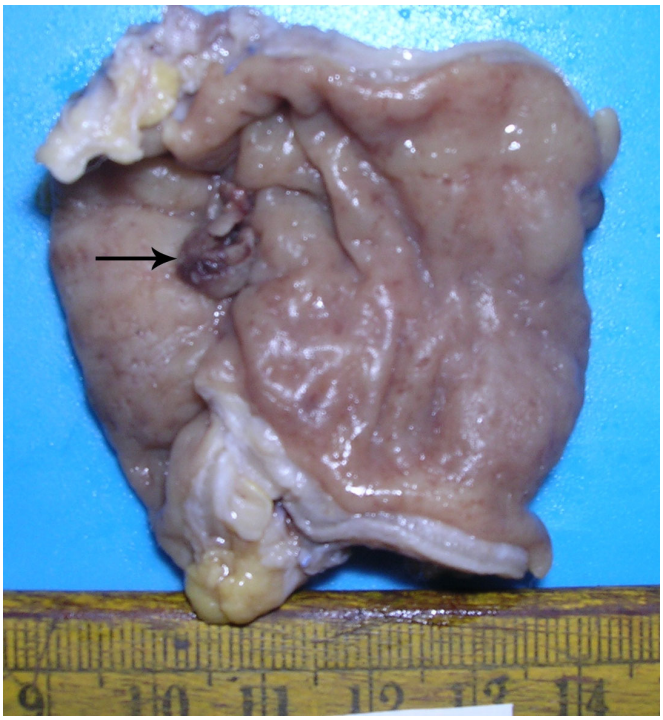

Figure 1: Gross impression of the resected bowel segment showing nodular lesion on the mucosal surface (arrow)

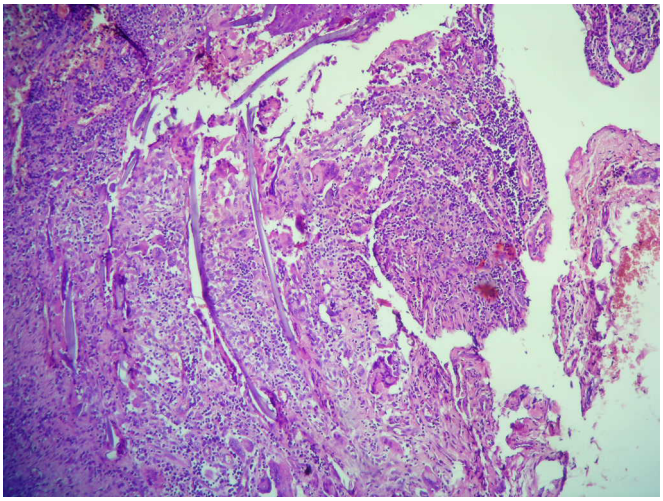

Figure 2: Photomicrograph showing foreign body surrounded by inflammation and foreign-body giant cell reaction. (H&E 100X)

Discussion

Surgical procedures are an integral part of treatment in

© Tropical Gastroenterology 2009

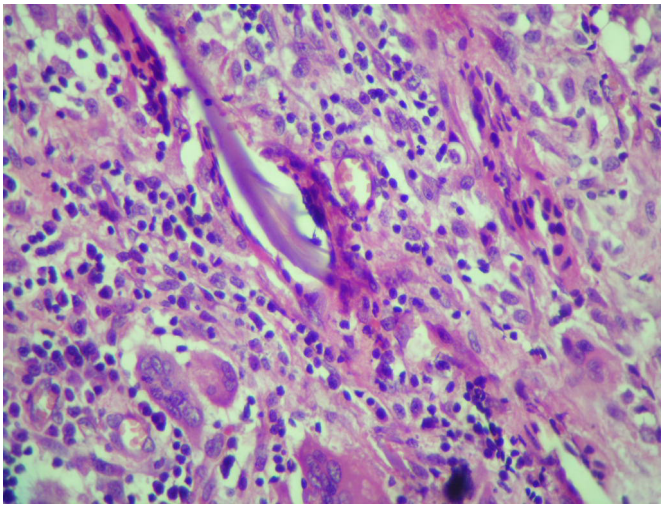

Figure 3: Suture material surrounded by foreign-body giant cells and inflammation. (H&E 400X)

modern medical science. They are, however fraught with inherent complications and side-effects. Surgeries invariably expose the human body to a large number of foreign material. These may be in the form of glove powder, gauze, lint, sutures, surgical clips, prosthetic implants or even locally applied hemostatic material.

Absorbable sutures are used in surgical practice so as not to elicit any significant foreign body reaction. However, suture granulomas are a well established histopathological entity. Shapiro[5] states that foreign body reaction to suture material shows a granulomatous response with histiocytes and foreign-body type giant cells around the suture material. Frequently, the suture material is seen within the macrophages and the giant cells. Nylon suture, talc, and glove powder are doubly refractile on polarising examination.[5] Luijendijk et al[1] undertook a study to determine the prevalence of foreign body granulomas in post-operative intra-abdominal adhesions and found suture material to be the most common foreign material associated with post-operative intra-abdominal adhesions. They observed that suture granulomas were seen in 25% of the patients with past history of abdominal surgery. Suture granulomas can also produce lesions mimicking cancers clinically and even radiologically.[3] In the present case, suture material was identified within the cytoplasm of the foreign body giant cells as well as extracellularly. It was also discerned as birefringrent on polarising examination.

Luijendijk et al[1] found starch granulomas in 5% of the patients with post-operative intra-abdominal adhesions. Using polarised light, glove starch powder can be recognised by the typical birefringrent Maltese crosses[1] in histological sections. Such Maltese crosses were not identifiable in the present case.

Gauze lint or cotton fibres, when retained in the body can elicit an exaggerated foreign body giant cell reaction. These may mimic slowly growing soft tissue tumours (textilomas) and can attain enormous sizes. The radiological features of such lesions have also been described.[6] Tinker et al[7] reported two cases of granulomatous peritonitis in which a fibre-like foreign material was identified on histology along with inflammatory and foreign-body giant cell reaction. These were confirmed as cellulose fibres from disposable surgical drapes and gowns that were birefringrent on polarisation and had a typical trilaminar configuration.

Resorbable and non-resorbable substances are used to achieve local hemostasis in the surgical bed intra-operatively. These may be composed of gelatin sponge, oxidised cellulose or microfibrillar collagen. Cotton- or rayon-based hemostats may also be used. These agents have been reported to cause mass lesions, most commonly following intra-abdominal surgery.[2] These may also produce symptomatic lesions like the abscess, as reported by Ibrahim et al.[8] Histologic examination shows a core of degenerating hemostatic agent surrounded by inflammatory and foreign body reaction.[2] No such material was used during surgery in the present case.

Blood, bile and material extruded from the gastrointestinal tract may also elicit a peritoneal inflammatory reaction causing post-operative adhesions.[1] Such contamination is more likely to occur in emergency laparotomies performed for acute obstruction or perforation. In the present case, the surgery was elective and adequately planned to avoid any such contamination.

Foreign chemicals can also be introduced into the body as a result of occupational and environmental exposure or drug abuse. Such exposure however causes systemic effects with functional impairment of the various organs.

To conclude, in spite of adequate precautions taken during surgery, inadvertent retention of foreign material inside the human body cannot be entirely avoided. Inflammatory and foreign body reactions to such materials can produce lesions mimicking cancer, clinically and radiologically. It is thus important for the histopathologist to be aware of such entities and be acquainted with the histomorphology of identifiable foreign substances.

References

1. Luijendijk RW, de Lange DC, Wauters CC, Hop WC, Duron JJ, Pailler JL, et al. Foreign material in post-operative adhesions. *Ann Surg*. 1996;**223**:242–8.
2. Ribalta T, McCutcheon IE, Neto AG, Gupta D, Kumar AJ, Biddle DA, et al. Textiloma (Gossypiboma) mimicking recurrent intracranial tumor. *Archives of Pathology and Laboratory Medicine*, 2004;**128**:749–58.
3. Epstein AJ, Russell EJ, Berlin L, Novetsky GJ, Lobo N, Miller SH, et al. Suture granuloma: an unusual cause of an enhancing ring lesion in the postoperative brain. *J Comput Assist Tomogr*. 1982;**64**:815–7.
4. Poyanli A, Bilge O, Kapran Y, Güven K. . Foreign body granuloma mimicking liver metastasis. *Br J Radiol*. 2005;**78**:752–4.
5. Philip E. Shapiro: Lever's Histopathology of the Skin, *8th. Edition. Lipincott-Raven Publishers, Philadelphia* 1997:pg.317.
6. Bellin M, Hornoy B, Richard F, Davy-Miallou C, Fadel Y, Zaim S, et al. Perirenal textiloma: MR and serial CT appearance. *Eur Radiol*. 1998;**8**:57–9.
7. Tinker MA, Burdman D, Deysine M, Teicher I, Platt N, Aufses AH Jr. Granulomatous peritonitis due to cellulose fibers from disposable surgical fabrics. *Ann Surg*. 1974;**180**:831–5.
8. Ibrahim MF, Aps C, Young CP. A foreign body reaction to Surgicel[R] mimicking an abscess following cardiac surgery. *Eur J Cardiothorac Surg*. 2002;**22**:489–90.

TRIPATHI PRACHI B
KINI SANGEETA
AMARAPURKAR ANJALI D
Corresponding Author: Dr. Anjali D Amarapurkar
Department of Pathology
TN Medical College &
BYL Nair Charitable Hospital
Mumbai- 400025
Email: anjali1963@gmail.com