

- Korean Surg Soc.* 2012;82:54-58
3. Al-Sheneber IF, Jaber T, Huttner I, Arseneau J, Loutfi A. Carcinosarcoma of the gallbladder: A case report and review of literature. *Saudi J Gastroenterol* 2002;8:22-4
 4. Huguet KL, Hughes CB, Hewitt WR. Gallbladder carcinosarcoma : a case report and literature review. *J Gastrointest Surg.* 2005;9:818-21

Initial Placement of a Percutaneous Balloon-Retained Gastrostomy using a transgastrostomic endoscope.

Introduction

The first percutaneous endoscopic gastrostomy (PEG) placement in our country, Algeria was reported seven years earlier by our team. Since that first report, only one hundred PEG have been performed. All PEG have been performed with the pull method reported by Gauderer and Ponsky in 1980.¹ The Balloon PEG (BPEG), a balloon-retained tube is often placed as a replacement for PEG. However, they can be placed as an initial tube feeding under endoscopic guidance by the introducer-type PEG technique first described by Russell et al. in 1984.² This method utilizes the Seldinger technique and requires a specific kit (trocar with peel-away sheet catheter). Recently, given the lack of both pull PEG kits and the peel-away sheet catheter despite the increasing demand, we attempted an initial placement of a BPEG, the only available PEG type. Without a peel-away sheet catheter, we had two challenges: the first one was to create the gastrocutaneous stoma and the second one was to dilate the stoma to introduce our BPEG tube. Necessary equipment for this procedure included a syringe with a small-gauge needle, a scalpel, local anesthetic, a large-gauge puncture needle sheath catheter, a wire, polypectomy snare or foreign body forceps, a reusable 24 Fr pull type PEG tube without external bumper, Savary-Gilliard guide wire, an 18 Fr BPEG (Wilson COOK) and a

small caliber endoscope (GIF XP-260; Olympus Optical Co., Ltd., Tokyo, Japan).

Case Report

First, a gastrocutaneous tract was created with the classic pull method. The procedure was performed after prior fasting of at least 6 h, under strict aseptic conditions, and antibiotic prophylaxis. The patient was positioned supine, under mild sedation. Two operators were required to create the gastrocutaneous stoma: one performed the endoscopy while the second worked from the abdominal site. After maximal air insufflations, the exact site of the PEG insertion was determined by gastroscopic transillumination using the small caliber endoscope orally inserted and with finger indentation.

The abdominal wall was cleaned with disinfectant and an incision was made under local anesthesia. The puncture needle was inserted through the incision into the stomach cavity under endoscopic guidance. Next, a wire was inserted into the stomach through the outer sheath of the puncture needle, grasped by a snare or a foreign body forceps, and pulled out by the endoscope through the mouth. The endoscope was then embedded in the pull type PEG tube without external bumper (**Figure 1A**). The whole PEG tube and the embedded endoscope was attached to the wire and pulled out through the gastrocutaneous tract creating and dilating the gastrocutaneous stoma (**Figure 1B**). Then the transgastrostomic endoscope was dis-embedded from the PEG tube. A Savary-Gilliard guide wire was then pushed through the scope to the cutaneous side and inserted in a BPEG. Simultaneously, the whole endoscope and BPEG tube on the metallic guide wire was pushed from the cutaneous side and pulled out through the mouth. Under direct endoscopic view, the BPEG was introduced into the stomach (**Figure 1C**) and the internal retention balloon inflated with the prefilled syringe (20 cc) (**Figure 1D**). Finally, the endoscope and the Savary-Gilliard guide wire were pulled out.

A total of 4 procedures of initial placement of BPEG tube were successfully performed in 4 patients. The classic introducer-type PEG technique requires smaller diameter feeding tubes, resulting in more frequent occlusion and dislodgement which may be reduced by

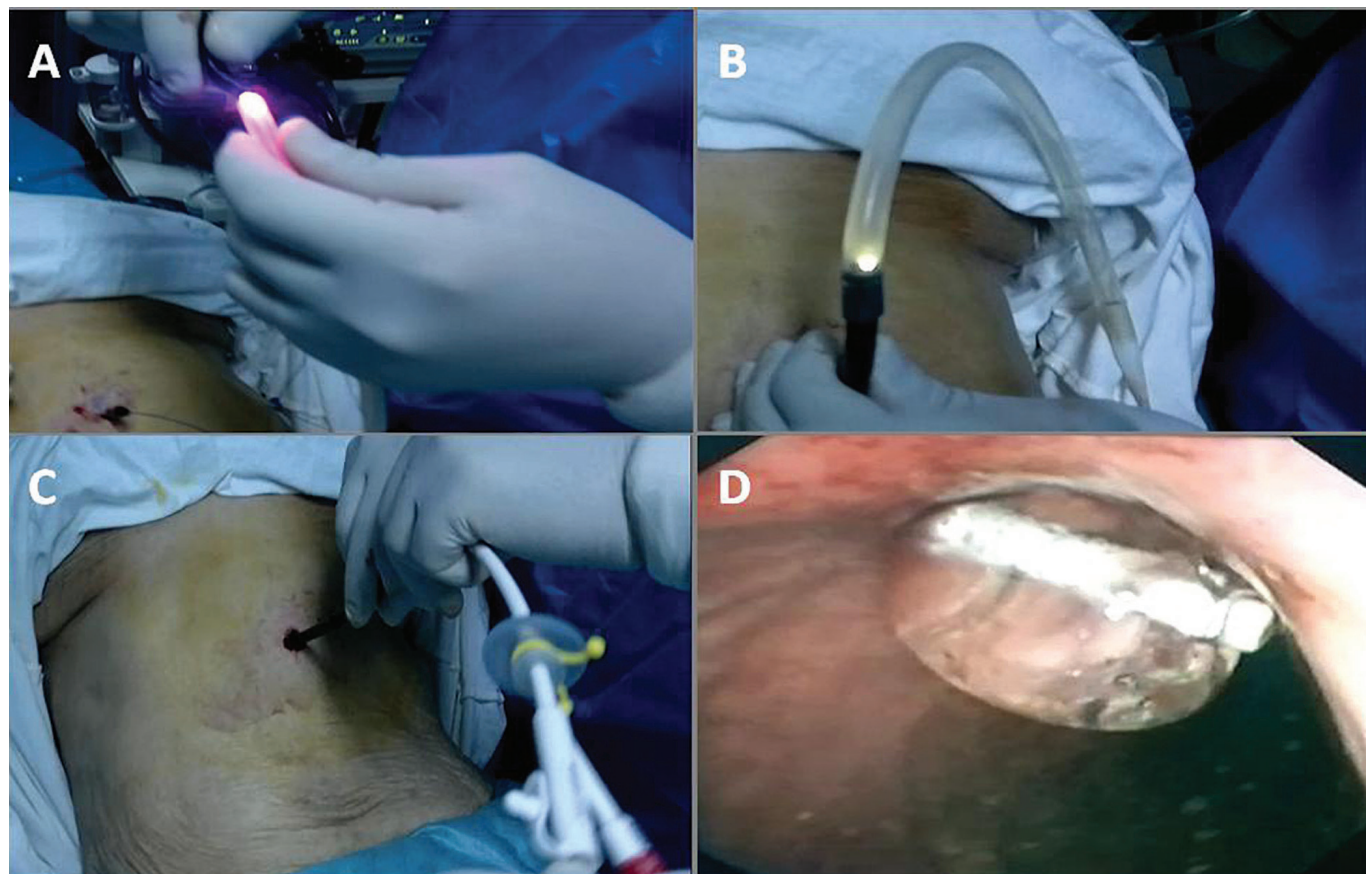


Figure 1a: The endoscope embedded in the 24 Fr pull type PEG tube; B: The whole 24 Fr pull type PEG tube and the embedded endoscope pulled out through the gastrocutaneous tract; C: The whole endoscope and the BPEG tube introduced into the stomach; D: The internal retention balloon inflated.

the use of gastropexy. The use of a transgastrostomic endoscope was reported for percutaneous endoscopic jejunostomy placement and was inserted through a mature gastrocutaneous tract from the abdominal side.³⁻⁶ Initial placement of BPEG using a transgastrostomic endoscope is easy and safe and should be attempted even in cases without a previous stoma. This method allows immediate enteral access and may be extended as an initial placement to all types of PEG tube replacement.

MOHAMMED AMINE BENATTA
 KELLOU NAILA
 HADJMATI SALAHEDDINE
 KEZZOULA DJAMEL
 KORDJANI SLIMANE
 REBIAI SOUAD

LAGOUNE HIND
 MEDDAH ABDELAZIZ

Correspondence: Mohammed Amine Benatta, Military Central Hospital Kouba Algiers, e-mail: benattaamine@yahoo.fr

References

1. Gauderer MW, Ponsky JL, Izant Jr RJ. Gastrostomy without laparotomy: a percutaneous endoscopic technique. *J Pediatr Surg.* 1980;15:872–5.
2. Russell TR, Brotman M, Norris F. Percutaneous gastrostomy. A new simplified and cost-effective technique. *Am J Surg.* 1984;148:132–7.
3. Chaurasia OP, Chang KJ. A novel technique for percutaneous endoscopic gastrojejunostomy tube placement. *Gastrointest Endosc.* 1995;42(2):165-168.

4. Baron TH. Direct percutaneous endoscopic jejunostomy through a mature gastrostomy tract. *Gastrointest Endosc.* 2002;56:946-947.
5. Adler DG, Gostout CJ, Baron TH. Percutaneous transgastric placement of jejunal feeding tubes with an ultrathin endoscope. *Gastrointest Endosc.* 2002;55:106-110
6. Nishiwaki S, Araki H, Shirakami Y, Kawaguchi J. Direct percutaneous endoscopic jejunostomy using a transgastrostomic endoscope in patients with previous endoscopic gastrostomy. *Endoscopy.* 2009;41(S 02),E36-E37.

Primary Aortoenteric fistula : An alarming entity warranting early diagnosis

Introduction

Aortoenteric fistulas (AEF) are communications between the aorta and a loop of the bowel. Primary AEF is a rare and challenging entity and requires awareness and a vigilant approach to reach the diagnosis. Autopsy findings suggest that the incidence of primary AEF range between 0.04% and 0.07%.¹ Despite advances in technology, an AEF is difficult to diagnose and treat and is associated with high mortality (65-100%) and morbidity.² The radiologist plays a pivotal role in reaching an accurate and precise diagnosis of AEF. Imaging tools such as ultrasound and multidetector contrast enhanced computed tomography (CECT) helps in making an accurate diagnosis and to differentiate it from other inflammatory mimickers. We describe a case report of a 46 year old woman presenting to the emergency with shock and a history of melena and was subsequently accurately diagnosed to have an aortoenteric fistula. The objective of presenting this case report is to discuss the radiological findings of primary aortoenteric fistula in a patient presenting with acute hemodynamic instability.

Case Report

A 46 year old woman was referred to the emergency with melena and shock. She had a history of sudden abdominal pain, vomiting and weakness for one day. She had a past history of on and off fever for the last 1 year with loss of weight and appetite. There was no history of previous abdominal vascular surgery. On systemic examination, the patient was found to have pallor, feeble pulse and was hemodynamically unstable with a blood pressure (BP) of 80/50, heart rate (HR) of 138 beats per minute, C reactive protein (CRP) of 96 and hemoglobin (Hb) of 6.2gm%. The patient had a further drop in hemoglobin to a Hb of 3.7gm% within 12 hours. To search for the cause of the sudden drop in hemoglobin and patient's worsening condition, a multidetector contrast enhanced computed tomography (CECT) was acquired on a 64 slice scanner (GE healthcare) by giving 100ml of iv contrast (300 mg /l) at the rate of 4.0 ml/sec and arterial phase images were acquired by bolus tracking followed by portal venous and delayed phase at 65 and 180 seconds respectively. However, despite being on resuscitative fluids and triple inotropes, the patient progressed to become severely hypotensive and had a cardio respiratory arrest from which she could not be revived even after cardiopulmonary resuscitation. The relatives of the patient didn't give consent for the autopsy.

Multidetector CECT revealed the presence of an active contrast extravasation from the infrarenal aorta in the left paraaortic location forming a large hematoma measuring 8.2 x 7 x 9.2 cm. Multiple air foci were seen adjacent to the aorta and in the hematoma, with direct communication with the fourth part (D4) of the duodenum (**Figure 1a,b**). A breach of 2.4 cm was seen in the posterior wall of the D4 segment of the duodenum (**Figure 2a**). The delayed images revealed the presence of contrast in the proximal jejunal loops (**Figure 2b**). The abdominal aorta, from the level of origin of the superior mesenteric artery to its bifurcation shows circumferential asymmetric mural thickening with irregular luminal narrowing (**Figure 3a**). Additional findings included chronic thrombosis of the left renal artery with atrophic left kidney and chronic thrombosis of the left common iliac artery and right external iliac artery (**Figure 3b,c**).

Discussion

An aortoenteric fistula (AEF) is the abnormal